

## Effects of Quebracho Tannin Extract on Testicular Ischemia-/Reperfusion

Zahra Ghotbitabar<sup>1</sup>, Ahmad Asghari<sup>2\*</sup> , Shahin Hassanpour<sup>3</sup> , Alireza Jahandideh<sup>2</sup>

1. Faculty of Veterinary Medicine, Science and Research Branch, Islamic Azad University, Tehran, Iran
2. Department of Clinical Sciences, Faculty of Veterinary Medicine, Science and Research Branch, Islamic Azad University, Tehran, Iran
3. Department of Basic Sciences, Faculty of Veterinary Medicine, Science and Research Branch, Islamic Azad University, Tehran, Iran

### Abstract

**BACKGROUND:** Ischemia/reperfusion (I/R) injury is one of the main pathophysiologic conditions of the testis. Although free radical scavenging properties of the tannins are approved, limited information exists on their antioxidant activities.

**OBJECTIVES:** The aim of this study was to evaluate the effect of quebracho tannin extract (QTE) on testicular I/R injury in rats.

**METHOD:** Thirty male Wistar rats were randomly divided into 5 experimental groups (n=6). One group was kept as control. In I/R group, rats were subjected to 4 hours I/20 hours R, and the group was intraperitoneally (ip) injected with saline 1 hour before R. In groups 3-5, rats were subjected to 4 hours I/20 hours R, and ip injected with QTE (100, 200, and 400 mg/kg) 1 hour before R. At the end of the study, left testis was removed for histological analysis and antioxidant measurement.

**RESULTS:** I/R resulted in degenerated seminiferous tubules and loss of spermatogenesis. Administration of QTE (200 and 400 mg/kg) to I/R rats showed many normal seminiferous tubules. Tissue malondialdehyde (MDA) levels significantly increased in I/R rats ( $P<0.05$ ) while QTE decreased IR-induced MDA level ( $P<0.05$ ). Experimental I/R significantly decreased superoxide dismutase (SOD) and glutathione peroxidase (GPx) activities ( $P<0.05$ ). Administration of QTE significantly increased tissue SOD and GPx activities in I/R rats ( $P<0.05$ ).

**CONCLUSIONS:** These findings suggested treatment with QTE had a beneficial effect against I/R.

**KEYWORDS:** Ischemia, *Quebracho tannin*, Rat, Reperfusion, Testicular

### Correspondence

Ahmad Asghari, Department of Clinical Sciences, Faculty of Veterinary Medicine, Science and Research Branch, Islamic Azad University, Tehran, Iran Tel: +98 (021) 65280370, Fax: +98 (021) 65280370,  
Email: [Dr.ahmad.asghari@gmail.com](mailto:Dr.ahmad.asghari@gmail.com)

Received: 2021-11-02

Accepted: 2022-01-11

Copyright © 2022. This is an open-access article distributed under the terms of the Creative Commons Attribution- 4.0 International License which permits Share, copy and redistribution of the material in any medium or format or adapt, remix, transform, and build upon the material for any purpose, even commercially.

#### How to Cite This Article

Ghotbitabar, Z., Asghari, A., Hassanpour, SH., Jahandideh, A. R. (2022). Effects of Quebracho Tannin Extract on Testicular Ischemia-/Reperfusion. *Iranian Journal of Veterinary Medicine*, 16(4), 423-431.

## Introduction

Testicular torsion has been known as one of the most serious disorders in the male reproduction system. The main pathophysiology of testicular torsion is ischemia/reperfusion (I/R) or cut-off of the blood supply that leads to testis injury (Moshkelani *et al.*, 2020; Tanriverdi *et al.*, 2021). In the I/R, interruption in blood supply leads to damage to tissues (Chouchani *et al.*, 2016). In the testicular I/R, the generation of reactive oxygen species (ROS) leads to tissue damage during the reperfusion. Excessive production of ROS leads to decreased antioxidant defenses in the seminal plasma (Arena *et al.*, 2017). Cellular antioxidants such as superoxide dismutase (SOD) and glutathione peroxidase (GPx) have essential effects in defense mechanisms against ROS-mediated cellular damage (Alabedi *et al.*, 2021). Several anti-inflammatory agents, antioxidants, and free radical scavengers were applied for the treatment of testicular I/R-induced male infertility (Lee *et al.*, 2021). However, because of side effects of the medicines, there are growing interest towards the application of medical plants in the treatment of testicular I/R (Hmood Jassim *et al.*, 2021).

Several polyphenolic compounds are produced during the growth and maturation of plants, which have an important role in plant fate. These substances are known as plant secondary metabolites. Tannins are polyphenolic compounds extensively found in the plants. The term “tannin” refers to “tanning” of skin in leather industry. Tannins are usually classified, based on their molecular structure, into hydrolysable tannins (HT) and condensed tannins (CT) (Chen *et al.*, 2019). Tannins have several biological properties including antimicrobial, anti-parasitic, antioxidant, anti-inflammatory, and antiviral effects (Buccioni *et al.*, 2017). Red quebracho species (*Schinopsis lorentzii* and *Schinopsis balansae*) are the most common and plentiful sources of CT (14–26% of heartwood). Extracts are regularly made from the bark or heartwood and for leather tanning (Fraga-Corral *et al.*, 2021). Quebracho tannin extract (QTE) is generally composed of 95% CT and 5% polysaccharides. QTE is a commercial source of CT and has been widely used for ruminant feeding to improve digestibility, nitrogen balance, energy partitioning, and milk production (Henke *et al.*, 2016). Antioxidant activity of the tannin-rich plants are responsible for their direct inhibition of ROS production.

ROS pathway plays a major role in the inflammatory response (Pinheiro *et al.*, 2013).

Although antioxidant activity of the QTE is well known, there is no report on its possible effectiveness in treatment of testicular I/R. Thus this study aimed to determine the therapeutic effect of QTE on experimental testicular I/R injury in rats.

## Materials and Methods

### Animals and Experimental Groups

Thirty healthy adult male Wistar rats (weight 250–300 g) were purchased from Pasteur Institute. Animals were kept under constant room temperature ( $20\pm 1^\circ\text{C}$ ) and relative humidity ( $42\pm 1\%$ ) on a 12-hour light/dark cycle. All animals had free access to commercial food and water. Rats were randomly divided into 5 experimental groups ( $n=6$ ). Groups were as follows: control group: animals intraperitoneally (ip) injected with saline, I/R group: rats subjected to 4-hour I/20-hour R periods, ip injected with saline 1 hour before R, group 3: rats subjected to 4-hour I/20-hour R periods, i.p. injected with 100 mg/kg of QTE 1 hour before R, group 4: animals subjected to 4-hour I/20-hour R periods, then 200 mg/kg of QTE ip injected 3 hours after I, and group 5: rats subjected to 4-hour I/20-hour R periods, then 400 mg/kg of QTE, ip injected 1 hour before R (Turkili *et al.*, 2012; Koksai *et al.*, 2012). This study was approved according to the Guidelines of the Animal Care provided by Research Committee of Islamic Azad University, Science and Research Branch, Tehran, Iran.

### Extract Procedure

Commercial Quebracho bark powder was provided, then heated with 80% ethanol (v/v) to  $80^\circ\text{C}$  for 2 hours. The extraction continued for further 10 hours at  $20^\circ\text{C}$ . The extract was then filtered through cheese cloth and evaporated with a rotary evaporator. The aqueous extract was freeze-dried for 48 hours, and the dried extract was homogenized with a mortar and pestle (Ribnicky *et al.*, 2009).

### Experimental Protocol

All surgical procedures were performed under anesthesia by ip injection of ketamine hydrochloride (60 mg/kg) and xylazine hydrochloride (10 mg/kg) followed by experimental testicular I/R (Sahin *et al.*,

2005). The upper left abdominal quadrant was approached through a midline laparotomy incision. During the surgical procedures, the body temperature was maintained with a heating pad. The testicular artery and vein of the left testis were occluded with a vascular clamp for 4 hours. Afterward, the clamp was removed, and the organ was allowed to reperfuse for 20 hours (Koksal *et al.*, 2012). In the end, the rats were euthanized with an overdose injection of pentobarbital (300 mg/kg, ip), peritoneum was then opened, and left testis was removed for further investigations. The testicle was divided into two sagittal sections and one half was fixed in Bouin solution. The second half of the testicle tissue was stored at -80°C for biochemical analysis (Minutoli *et al.*, 2005).

### Tissue Processing

The tissue was fixed in Bouin solution (7.5 mL saturated picric acid, 2.65 mL glacial acetic acid, and 2.5 mL 7% formaldehyde), post-fixed in 70% alcohol, and embedded in paraffin blocks. A tissue section (5 µm) was obtained, deparaffinized, and stained with hematoxylin and eosin (H&E). The testicular tissue was evaluated in a random order with standard light microscopy by an observer who was unaware to which group the rat belonged (Dal Lago and Lucke, 1973). Then, testis tissue samples from the experimental rats were fixed in Bouin solution for complete fixation and processed for paraffin sectioning. A tissue section at 5 µm thickness was taken and stained with H&E. The testis sections were graded numerically to assess the degree of histological changes associated with seminiferous tubule injury as previously described by Johnsen (1970) as:

- 10: Complete spermatogenesis and perfect tubules
- 9: Many spermatozoa present but disorganized spermatogenesis
- 8: Only a few spermatozoa present
- 7: No spermatozoa but many spermatids present
- 6: Only a few spermatids present
- 5: No spermatozoa or spermatids present but many spermatocytes present
- 4: Only a few spermatocytes present

- 3: Only spermatogonia present
- 2: No germ cells present
- 1: Neither germ cells nor Sertoli cells present

### Antioxidant Activity

At the end of the tests, testis samples were obtained and tissue MDA, SOD, GPx, and total antioxidant status (TAS) were determined using Zell Bio GmbH (Germany) assay kits.

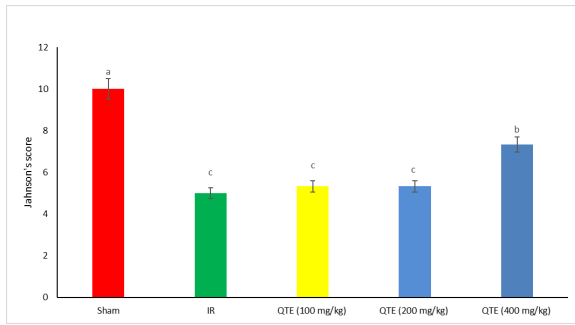
### Statistical analysis

Data were prepared in Excel, and the parametric data were analyzed with one-way analysis of variance (ANOVA) using the SPSS software version 16.0 for Windows (SPSS, Inc., Chicago, IL., USA). Data were expressed as mean ± standard error (SE). Where heterogeneity occurred, the groups were separated using Tukey's multiple comparison test. The Kruskal-Wallis test was used to compare group medians for histopathological scores. P-value < 0.05 was considered to denote significant differences between the groups.

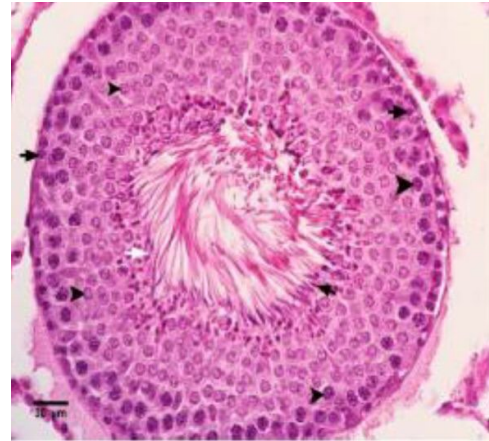## Results

### Histopathological Activity of the QTE

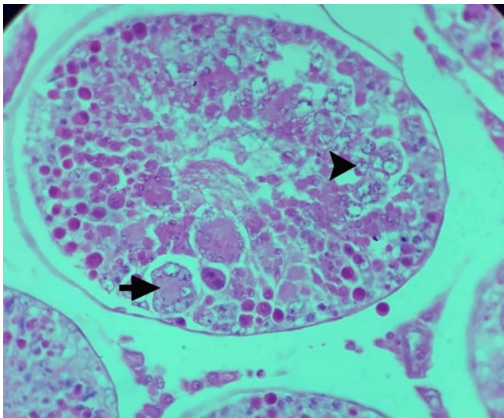
The effect of QTE on testicular histopathology is shown in [Figures 1-6](#). As seen, the lowest effect was seen at QTE (100 mg/kg) while QTE (200 and 400 mg/kg) had better results on histological indexes compared to the control group ( $P < 0.05$ ). According to [Figure 2](#), rats in the control group showed normal seminiferous tubules and spermatogenesis with spermatocytes, sertoli, and spermatozoa. Based on [Figure 3](#), in I/R rats, seminiferous tubules were degenerated and loss of spermatogenesis with a few spermatocytes was observed. Based on the results shown in [Figure 4](#), administration of the QTE (100 mg/kg) after I/R induction led to degenerated seminiferous tubules and loss of spermatogenesis with a few spermatocytes. While administration of the QTE (200 mg/kg) improved testis characteristics with a few normal seminiferous tubules and spermatocytes in seminiferous tubules in experimental I/R-induced rats ([Figure 5](#)). Administration of the QTE (400 mg/kg) to I/R rats improved testis characteristics with a few normal seminiferous tubules and spermatocytes in seminiferous tubules ([Figure 6](#)).



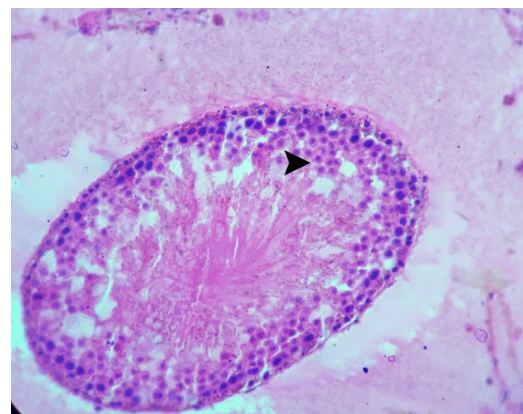
**Figure 1.** Scores of histological changes associated with seminiferous tubules injury in experimental I/R rat. Different letters (a-c) indicate significant differences between the treatments ( $P < 0.05$ ).



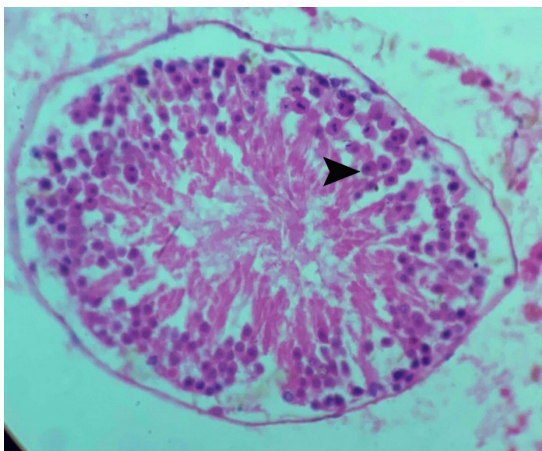
**Figure 2.** Testis section of control rats showing normal seminiferous tubules (arrow) and interstitial cells (arrow head) between the tubules. H&E: Hematoxylin and eosin.



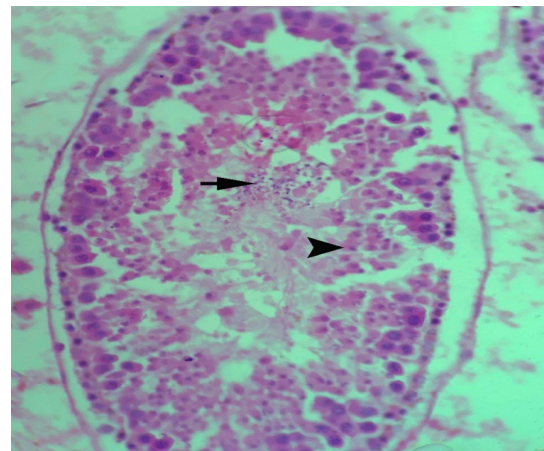
**Figure 3.** Testis section of I/R rats showing degenerated seminiferous tubules (arrow) and loss of spermatogenesis. H&E: Hematoxylin and eosin.



**Figure 4.** Testis section of QTE-administered (100 mg/kg) I/R rats showing seminiferous tubules (arrow) with a few spermatocyte and interstitial cells (arrow head) between the tubules. H&E: Hematoxylin and eosin.



**Figure 5.** Testis section of QTE-administered (200 mg/kg) I/R rats showing seminiferous tubules (arrow) with a few spermatocyte and interstitial cells (arrow head) between the tubules. H&E: Hematoxylin and eosin.



**Figure 6.** Testis section of QTE-administered (400 mg/kg) I/R rats showing many normal seminiferous tubules (arrow). H&E: Hematoxylin and eosin.

### Effect of QTE on Antioxidant Activity

According to [Table 1](#), tissue MDA levels significantly increased in I/R rats ( $P<0.05$ ) while QTE (200 and 400 mg/kg) decreased the I/R-induced MDA level ( $P<0.05$ ). Experimental I/R significantly decreased the tissue SOD and GPx concentrations

compared to the control group ( $P<0.05$ ). Administration of the QTE (200 and 400 mg/kg) significantly increased the tissue SOD activity in I/R rats ( $P<0.05$ ). Furthermore, QTE (200 and 400 mg/kg) increased the tissue GPx levels in I/R rats ( $P<0.05$ ). No significant difference was observed between the studied groups in terms of tissue TAS level ( $P>0.05$ ).

**Table 1.** Effect of different levels *Quebracho tannin* extract on testis values of malondialdehyde, superoxide dismutase, glutathione peroxidase and total antioxidant status in I/R rat

Group	MDA (nmol/g tissue)	SOD (IU/ mg tissue)	GPx (IU/mg tissue)	TAS (nmol/ g tissue)
Control	25.20±0.24 <sup>c</sup>	19.7±0.10 <sup>a</sup>	49.70±0.10 <sup>a</sup>	1.50±0.40
I/R	77.20±0.30 <sup>a</sup>	9.1±0.30 <sup>c</sup>	21.60±0.40 <sup>c</sup>	0.80±0.20
QTE (100 mg/kg)	61.90±0.30 <sup>a</sup>	10.30±0.20 <sup>c</sup>	22.90±0.20 <sup>c</sup>	0.90±0.40
QTE (200 mg/kg)	44.20±0.20 <sup>b</sup>	15.80±0.40 <sup>a</sup>	34.20±0.30 <sup>b</sup>	1.20±0.40
QTE (400 mg/kg)	28.14±0.20 <sup>c</sup>	17.60±0.10 <sup>b</sup>	44.70±0.40 <sup>a</sup>	1.40±0.10

I/R: Ischemia/reperfusion, *Quebracho tannin* extract: QTE, MDA: malondialdehyde, SOD: superoxide dismutase, GPx: glutathione peroxidase, TAS: total antioxidant status. Different letters (a-c) indicate significant differences between treatments ( $P<0.05$ ).

### Discussion

To the best of our knowledge, there are limited studies describing the role of QTE in oxidative damage and testicular pathology in testicular IR injury in rat. As observed in this study, I/R led to degenerated seminiferous tubules and loss of spermatogenesis. Administration of the QTE (200 and 400 mg/kg) to I/R rats showed many normal seminiferous tubules. Tissue MDA levels significantly increased in I/R rats while QTE decreased I/R-induced MDA level. Experimental I/R significantly decreased SOD and GPx activities. While administration of the QTE significantly increased tissue SOD and GPx activities in I/R rats.

Testicular torsion leads to ischemia and reperfusion with detorsion of the twisted testicle leading to morphological damage to testicular tissue. Additionally, post-ischemic reperfusion amplifies further tissue damage and apoptosis (Tuglu *et al.*, 2015). Despite vast progresses during the past decade in this area, I/R injury remains a clinically challenging problem (Abdallah, 2021). In initial stage of I/R injury, ROS is released after reperfusion, then endothelial dysfunction or neutrophil infiltration

triggers the oxidative damage (Zadeh *et al.*, 2019). In this regard, Wei *et al.* (2011) reported 2 hours of unilateral testicular torsion followed by detorsion changes in MDA, SOD, and CAT activities. ROS include hydrogen peroxide and unstable free radicals with unpaired electrons in their outer orbits. Excessive ROS or decreased antioxidant defenses in the seminal plasma damages spermatozoa via oxidative stress (Shamsi-Gamchi *et al.*, 2018). In this regard, Ahmadvand *et al.* (2017) reported that pretreatment with gallic acid as an antioxidant agent has protective effects on oxidative stress markers in renal I/R injury in rats. However, there is no report on the application of *Quebracho* on I/R injury and we were not able to compare our findings with previous reports. Recently, Reggi *et al.* (2020) demonstrated *Quebracho*, and chestnut tannin extracts exert growth inhibitory activity against *E. coli* as well as increasing cell viability modulation activities. Tannins can inhibit the growth of some pathogenic bacterial species without adverse effect on the physiological growth pattern of gastrointestinal tract. Moreover, dietary QT increased the antioxidant capacity of liver and plasma in sheep (López-Andrés *et*

*al.*, 2013). Supplementing the sheep with polyphenols and condensed tannins elevated SOD levels in the plasma (Sgorlon *et al.* 2006). Remarkably, Larrosa *et al.* (2010) showed that hydrolysable tannins in an indirect manner decrease the activity of antioxidant system in monogastric animals.

Oxidative stress, resulting in an imbalance between the production of oxygen free radicals and antioxidant capacity, damages the biological macromolecules and causes the disruption in normal metabolism and physiology (Zhang *et al.*, 2012). Sperm membranes contain high levels of polyunsaturated fatty acids (PUFAs) in spermatozoa which are susceptible to be attacked by ROS (Hadwan *et al.*, 2014). MDA is the end product of lipid peroxidation, and the elevation in testicle MDA level is a marker of extent of oxidative stress that leads to infertility (Hsieh *et al.*, 2006). Our findings suggested treatment with QTE had a beneficial effect against I/R.

## References

- Abdallah, H. M. (2021). New trends in pharmacological treatment of acute kidney injury. *Asian Pacific Journal of Tropical Biomedicine*, 11(7), 285. [DOI:10.4103/2221-1691.317241]
- Ahmadvand, H., Babaeenezhad, E., Moradi, F. H., & Venool, A. C. (2017). Effect of gallic acid on liver oxidative stress markers in renal ischemia-reperfusion injury in rats. *Annals of Research in Antioxidants*, 2(2).
- Alabedi, T., AL-Baghdady, H.F., Alahmer, M.A., Bustani, G.S., Al-Dhalimy, A.M. (2021) Effects of Ocimum tenuiflorum on Induced Testicular Degeneration by Filgrastim in Wistar Rats. *Archives of Razi Institute*, 76(5):1555-1559.
- Arena, S., Iacona, R., Antonuccio, P., Russo, T., Salvo, V., Gitto, E., ... & Romeo, C. (2017). Medical perspective in testicular ischemia-reperfusion injury. *Experimental and Therapeutic Medicine*, 13(5), 2115-2122. [DOI:10.3892/etm.2017.4289] [PMID] [PMCID]
- Buccioni, A., Pallara, G., Pastorelli, R., Bellini, L., Capucci, A., Mannelli, F., ... & Pauselli, M. (2017). Effect of dietary chestnut or quebracho tannin supplementation on microbial community and fatty acid profile in the rumen of dairy ewes. *BioMed Research International*, 2017. [DOI:10.1155/2017/4969076] [PMID] [PMCID]
- Cardullo, N., Muccilli, V., Cunsolo, V., & Tringali, C. (2020). Mass spectrometry and 1H-NMR study of Schinopsis lorentzii (Quebracho) tannins as a source of hypoglycemic and antioxidant principles. *Molecules*, 25(14), 3257. [DOI:10.3390/molecules25143257] [PMID] [PMCID]
- Chen, F., Tang, Q., Ma, H., Bian, K., Seeram, N. P., & Li, D. (2019). Hydrolyzable Tannins are iron chelators that inhibit DNA repair enzyme ALKBH2. *Chemical Research in Toxicology*, 32(6), 1082-1086. [PMCID] [DOI:10.1021/acs.chemrestox.8b00398] [PMID]
- Chouchani, E. T., Pell, V. R., James, A. M., Work, L. M., Saeb-Parsy, K., Frezza, C., ... & Murphy, M. P. (2016). A unifying mechanism for mitochondrial superoxide production during ischemia-reperfusion injury. *Cell Metabolism*, 23(2), 254-263. [DOI:10.1016/j.cmet.2015.12.009] [PMID]

## Conclusion

It can be concluded that QTE improves the antioxidant capacity of tissues via an indirect effect, possibly by enhancing the tissue endogenous antioxidant activity or by participating in the regeneration of other antioxidant compounds. This study was an animal model to investigate the antioxidant activity of QTE in testicular I/R injury. This information can be used as basic data for further investigations on antioxidant agents involved in human testicular torsion

## Acknowledgments

Authors impress fully thanks to all co-workers.

## Conflict of Interest

The authors declared no conflict of interest.

- Lago, A. D., & Lucke, S. (1973). A method of fixing rat testis for light and electron microscopy. *Stain Technology*, 48(6), 289-295. [DOI:10.3109/10520297309116644] [PMID]
- Fraga-Corral, M., Otero, P., Cassani, L., Echave, J., Garcia-Oliveira, P., Carpena, M., ... & Simal-Gandara, J. (2021). Traditional applications of tannin rich extracts supported by scientific data: Chemical composition, bioavailability and bioaccessibility. *Foods*, 10(2), 251. [DOI:10.3390/foods10020251] [PMID] [PMCID]
- Hadwan, M. H., Almashhedy, L. A., & Alsaman, A. R. S. (2014). Study of the effects of oral zinc supplementation on peroxynitrite levels, arginase activity and NO synthase activity in seminal plasma of Iraqi asthenospermic patients. *Reproductive Biology and Endocrinology*, 12(1), 1-8. [DOI:10.1186/1477-7827-12-1] [PMID] [PMCID]
- Henke, A., Dickhoefer, U., Westreicher-Kristen, E., Knappstein, K., Molkentin, J., Hasler, M., & Susenbeth, A. (2017). Effect of dietary Quebracho tannin extract on feed intake, digestibility, excretion of urinary purine derivatives and milk production in dairy cows. *Archives of Animal Nutrition*, 71(1), 37-53. [DOI:10.1080/1745039X.2016.1250541] [PMID]
- Hmood Jassim, A., Abed, A. S., Kareem Thamer, A., Judi, H. K., & Enad, A. H. (2022). Effect of Letrozole Administration as a Selective Aromatase Inhibitor on Male Rat's Reproductive Performance. *Archives of Razi Institute*, 77(1), 367-373. [DOI:10.10.22092/ARI.2021.356539.1864]
- Hsieh, Y. Y., Chang, C. C., & Lin, C. S. (2006). Seminal malondialdehyde concentration but not glutathione peroxidase activity is negatively correlated with seminal concentration and motility. *International Journal of Biological Sciences*, 2(1), 23. [DOI:10.7150/ijbs.2.23] [PMID] [PMCID]
- Johnsen, S. G. (1970). Testicular biopsy score count—a method for registration of spermatogenesis in human testes: normal values and results in 335 hypogonadal males. *Hormone Research in Paediatrics*, 1(1), 2-25. [DOI:10.1159/000178170] [PMID]
- Koksal, M., Oğuz, E., Baba, F., Eren, M. A., Ciftci, H., Demir, M. E., ... & Ulas, T. (2012). Effects of melatonin on testis histology, oxidative stress and spermatogenesis after experimental testis ischemia-reperfusion in rats. *European Review for Medical and Pharmacological Sciences*, 16(5), 582-588.
- Larrosa, M., García-Conesa, M. T., Espín, J. C., & Tomás-Barberán, F. A. (2010). Ellagitannins, ellagic acid and vascular health. *Molecular Aspects of Medicine*, 31(6), 513-539. [DOI:10.1016/j.mam.2010.09.005] [PMID]
- Lee, J. W., Hwang, E. T., & Han, J. S. (2021). Protective Effects of Topical Application of Nitrite on Testicular Ischemia-Reperfusion Injury in Rats. *Oxidative Medicine and Cellular Longevity*, 2021. [DOI:10.1155/2021/5514537]
- López-Andrés, P., Luciano, G., Vasta, V., Gibson, T. M., Biondi, L., Priolo, A., & Mueller-Harvey, I. (2013). Dietary quebracho tannins are not absorbed, but increase the antioxidant capacity of liver and plasma in sheep. *British Journal of Nutrition*, 110(4), 632-639. [DOI:10.1017/S0007114512005703] [PMID]
- Minutoli, L., Antonuccio, P., Romeo, C., Nicotina, P. A., Bitto, A., Arena, S., ... & Squadrito, F. (2005). Evidence for a role of mitogen-activated protein kinase 3/mitogen-activated protein kinase in the development of testicular ischemia-reperfusion injury. *Biology of Reproduction*, 73(4), 730-736. [DOI:10.1095/biolreprod.105.040741] [PMID]
- Moshkelani, S., Asghari, A., Abedi, G., Jahandideh, A., & Mortazavi, P. (2020). Effects of Magnesium Sulfate Administration on Testicular Ischemia/Reperfusion Injury in Rats. *Archives of Razi Institute*, 75(1), 83.
- Pinheiro, M. M., Fernandes, S. B., Fingolo, C. E., Boylan, F., & Fernandes, P. D. (2013). Anti-inflammatory activity of ethanol extract and fractions from *Couroupita guianensis* Aublet leaves. *Journal of Ethnopharmacology*, 146(1), 324-330. [DOI:10.1016/j.jep.2012.12.053] [PMID]
- Reggi, S., Giromini, C., Dell'Anno, M., Baldi, A., Rebbucci, R., & Rossi, L. (2020). In vitro digestion of chestnut and quebracho tannin extracts: Antimicrobial effect, antioxidant capacity and cytomodulatory activity in swine intestinal IPEC-J2 cells. *Animals*, 10(2), 195. [DOI:10.3390/ani10020195] [PMID] [PMCID]
- Ribnicky, D. M., Kuhn, P., Poulev, A., Logendra, S., Zuberi, A., Cefalu, W. T., & Raskin, I. (2009). Improved absorption and bioactivity of active compounds from an anti-diabetic extract of *Artemisia dracuncululus* L. *International Journal of Pharmaceutics*, 370(1-2), 87-92. [DOI:10.1016/j.ijpharm.2008.11.012] [PMID] [PMCID]
- Sahin, Z., Bayram, Z., Celik-Ozenci, C., Akkoyunlu, G., Seval, Y., Erdogru, T., ... & Demir, R. (2005). Effect of experimental varicocele on the expressions of Notch 1, 2, and 3 in rat testes: an immunohistochemical study. *Fertility and Sterility*, 83(1), 86-94. [DOI:10.1016/j.fertnstert.2004.09.006] [PMID]

- Sgorlon, S., Stradaoli, G., Zanin, D., & Stefanon, B. (2006). Biochemical and molecular responses to antioxidant supplementation in sheep. *Small Ruminant Research*, 64(1-2), 143-151. [DOI:10.1016/j.smallrumres.2005.04.009]
- Shamsi-Gamchi, N., Razi, M., & Behfar, M. (2018). Testicular torsion and reperfusion: evidences for biochemical and molecular alterations. *Cell Stress and Chaperones*, 23(3), 429-439. [DOI:10.1007/s12192-017-0855-0] [PMID] [PMCID]
- Tanriverdi, H. I., Şenel, U., Gevrek, F., & Akbaş, A. (2021). Protective effect of famotidine on ischemia-reperfusion injury following testicular torsion in rats. *Journal of Pediatric Urology*, 17(2), 167-e1. [DOI:10.1016/j.jpuro.2020.09.019] [PMID]
- Tuglu, D., Yuvanc, E., Yılmaz, E., Gencay, I. Y., Atasoy, P., Kisa, U., & Batislam, E. (2015). The antioxidant effect of dexmedetomidine on testicular ischemia-reperfusion injury. *Acta Cirurgica Brasileira*, 30, 414-421. [DOI:10.1590/S0102-865020150060000007] [PMID]
- Turkili, B., Kurcer, Z., Dengiz, G. O., Kandemir, N. O., Mungan, G., Ozacmak, V. H., & Banoglu, Z. N. (2012). Role of angiotensin and endothelin in testicular ischemia reperfusion injury. *International Journal of Urology*, 19(3), 257-263. [DOI:10.1111/j.1442-2042.2011.02924.x] [PMID]
- Wei, S. M., Yan, Z. Z., & Zhou, J. (2011). Protective effect of rutin on testicular ischemia-reperfusion injury. *Journal of Pediatric Surgery*, 46(7), 1419-1424. [DOI:10.1016/j.jpedsurg.2010.09.044] [PMID]
- Zadeh, J. K., Garcia-Bardon, A., Hartmann, E. K., Pfeiffer, N., Omran, W., Ludwig, M., ... & Gericke, A. (2019). Short-time ocular ischemia induces vascular endothelial dysfunction and ganglion cell loss in the pig retina. *International Journal of Molecular Sciences*, 20(19), 4685. [DOI:10.3390/ijms20194685] [PMID] [PMCID]
- Zhang, X., Zhang, H., Zhou, N., Xu, J., Si, M., Jia, Z., ... & Zhang, H. (2015). Tannic acid modulates excitability of sensory neurons and nociceptive behavior and the Ionic mechanism. *European Journal of Pharmacology*, 764, 633-642. [DOI:10.1016/j.ejphar.2015.06.048] [PMID].



## اثرات تجویز عصاره تانن کبراکو بر آسیب متعاقب ایسکمی/رپرفیوژن بیضه در موش صحرایی

زهرا قطبی تبار<sup>۱</sup>، احمد اصغری<sup>۲\*</sup>، شاهین حسن پور<sup>۳</sup>، علیرضا جهانانیده<sup>۲</sup><sup>۱</sup> دانشکده دامپزشکی، واحد علوم و تحقیقات، دانشگاه آزاد اسلامی، تهران، ایران<sup>۲</sup> گروه علوم درمانگاهی، دانشکده دامپزشکی، واحد علوم و تحقیقات، دانشگاه آزاد اسلامی، تهران، ایران<sup>۳</sup> گروه علوم پایه، دانشکده دامپزشکی، واحد علوم و تحقیقات، دانشگاه آزاد اسلامی، تهران، ایران

(دریافت مقاله: ۱۱ آبان ماه ۱۴۰۰، پذیرش نهایی: ۲۱ دی ماه ۱۴۰۰)

**زمینه مطالعه:** آسیب ایسکمی/رپرفیوژن یکی از مهمترین شرایط پاتوفیزیولوژیک بیضه است. علیرغم اینکه خاصیت مهاري تانن‌ها بر رادیکال‌های آزاد تأیید شده است، اطلاعات محدودی برای فعالیت آنتی‌اکسیدانی آن وجود دارد.

**هدف:** هدف از این مطالعه درک اثر تجویز عصاره کبراکو تانن (QTE) بر آسیب ایسکمی/رپرفیوژن بیضه در موش صحرایی بود.

**روش کار:** ۳۰ قطعه موش صحرایی نر نژاد ویستار به طور تصادفی به ۵ گروه آزمایش (۶ نفر) تقسیم شدند. گروه به‌عنوان کنترل نگه داشته شد. موش‌های گروه ایسکمی/رپرفیوژن تحت دوره ۴ ساعته ایسکمی و ۲۰ ساعت رپرفیوژن قرار گرفتند و تزریق صفاقی سالین ۱ ساعت قبل از رپرفیوژن انجام شد. در گروه‌های ۳-۵ سر موش تحت دوره ۴ ساعته ایسکمی و ۲۰ ساعت رپرفیوژن قرار گرفتند و تزریق صفاقی QTE (۱۰۰، ۲۰۰ و ۴۰۰ میلی‌گرم/کیلوگرم) را ۱ ساعت قبل از رپرفیوژن دریافت کردند. در پایان مطالعه، بیضه چپ برای تجزیه و تحلیل بافت‌شناسی و اندازه‌گیری آنتی‌اکسیدان برداشته شد.

**نتایج:** با توجه به نتایج ایسکمی/رپرفیوژن منجر به انحطاط لوله‌های منی و از بین رفتن اسپرماتوزن شد. تجویز QTE (۲۰۰ و ۴۰۰ میلی‌گرم/کیلوگرم) به دنبال ایسکمی/رپرفیوژن تعداد زیادی لوله طبیعی منی برگ را نشان می‌دهد. ایسکمی/رپرفیوژن به‌طور معنی‌داری موجب افزایش سطح مالون دی‌آلدهید در بافت بیضه شد درحالی‌که تجویز QTE موجب کاهش مقادیر آن شد ( $P < 0.05$ ). ایسکمی/رپرفیوژن به‌طور معنی‌داری فعالیت سوپراکسید دیسموتاز و گلوکاتاتیون پراکسیداز را به کاهش داد ( $P < 0.05$ ). تجویز QTE موجب به‌طور قابل توجهی فعالیت دیسموتاز و گلوکاتاتیون پراکسیداز بیضه را در موش‌های دچار ایسکمی/رپرفیوژن افزایش داد ( $P < 0.05$ ).

**نتیجه‌گیری نهایی:** این یافته‌ها نشان می‌دهد که درمان با QTE تأثیر مفیدی در برابر ایسکمی/رپرفیوژن دارد.

**واژه‌های کلیدی:** تانن کبراکو، ایسکمی/رپرفیوژن، بیضه، موش صحرایی

نویسنده مسئول: احمد اصغری، گروه علوم درمانگاهی، دانشکده دامپزشکی، واحد علوم و تحقیقات، دانشگاه آزاد اسلامی، تهران، ایران.

ایمیل: [Dr.ahmad.asghari@srbiau.ac.ir](mailto:Dr.ahmad.asghari@srbiau.ac.ir)