

## Presentation of dermatophyte lesions on different sites of adult cattle

Khosravi, A.R.<sup>1\*</sup>, Shokri, H.<sup>1</sup>, Taghipour Bazargani, T.<sup>2</sup>, Ramak Yahyaraeyat, R.<sup>1</sup>, Ghiyasi, M.<sup>1</sup>

<sup>1</sup>*Mycology Research Center, Faculty of Veterinary Medicine, University of Tehran, Tehran-Iran.*

<sup>2</sup>*Department of Clinical Sciences, Faculty of Veterinary Medicine, University of Tehran, Tehran-Iran.*

(Received 16 January 2007, Accepted 12 November 2007)

**Abstract:** Seventy cattle suspected to dermatophytosis were examined between March and April 2003. The samples were taken from different lesions by scraping method. Direct microscopic examination and culture were carried out. The mean of infection duration was 2 weeks. Forty-three cases were appeared with positive clinical signs of dermatophytosis and 27 cases were asymptomatic. The etiologic agent of the infection was only *Trichophyton verrucosum*. A significant relation was observed between the frequency of head and neck lesions and other sites. There was a significant difference between the frequency of head lesions and other sites. Since human dermatophyte infections due to *Trichophyton verrucosum* have been reported repeatedly in Iran, it is necessary to design a preventive program such as developing an effective vaccine against dermatophytosis into the future.

**Key words:** dermatophytosis, *Trichophyton verrucosum*, cattle.

### Introduction

Dermatophytosis is a superficial infection of the keratinized tissues of epidermis, hair and nail caused by dermatophytes (Khosravi, Kordbacheh and Bokae, 1994). Dermatophytes have a worldwide geographical distribution. Infection with these organisms occurs frequently in animals, specially cat, dog, cattle, sheep, and horse (Vancutsem and Rochett, 1991). Several species of *Trichophyton* and *Microsporum* may cause dermatophyte infections in animals. *Trichophyton verrucosum* (*T. verrucosum*) is a zoophilic dermatophyte, as the most frequently agent with seasonal prevalence in ruminants, especially in cattle (Khosravi and Mahmoudi, 2003; Rippon, 1988). Lesions occur commonly on the head and neck. The initial lesions are discrete, grayish-white, crusty dry areas with a few brittle hairs. Some areas may become suppurative and thickly crusted (Vancutsem and Rochett, 1991). Regarding to the

other investigator findings, *T. verrucosum* can survive on the cattle skin without causing any clinical signs (Khosravi, Kordbacheh and Bokae, 1994; Vancutsem and Rochett, 1991). These animals act as normal carriers. On the other hand, infective arthroconidia on the scales can survive for a long time (Mackenzie *et al.*, 1986; Moghadami and Emami, 1986). It has been pointed out repeatedly that these animals act as a source of human dermatophytosis (Vancutsem and Rochett, 1991). Thus, it would be important to develop an effective vaccine to provide a protection against the infection in cattle. The aims of the present study were to isolate and identify the causative fungi of dermatophytosis and to determine the distribution of lesions on different sites of cattle body.

### Materials and Methods

In this study, 70 cattle suspected of having ringworm were examined clinically, between March and April 2003, for detecting of dermatophytosis

\* Corresponding author's email: khosravi@ut.ac.ir, Tel: 021- 61117151, Fax: 021-66933222



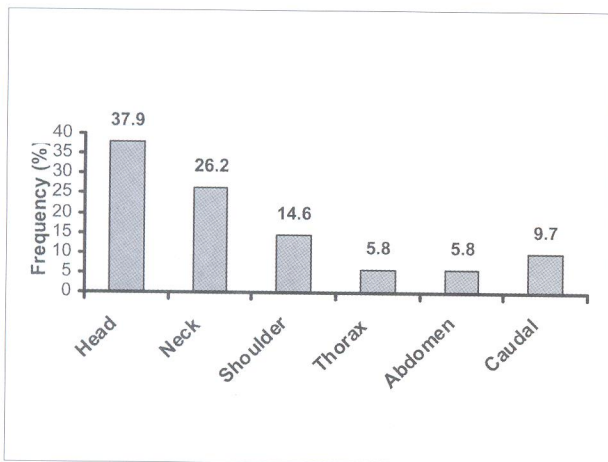


Figure 1. Distribution of dermatophyte lesions based on different sites of cattle body.

lesions in different sites of body (head, trunk, cranial and caudal limbs). The lesions consisted of scaling, annular plaques, hair loss and crusts. The surface of the affected area was first rubbed with a cotton swab impregnated with 70 % ethyl alcohol to remove surface adhering organisms. Skin scales were collected by scraping of the margin of the lesion using a sterile scalpel blade into sterile Petri dish, and transferred to Mycology Research Center, Faculty of Veterinary Medicine, University of Tehran. Direct microscopic examination was performed by 10 % KOH/ DMSO or lactophenol cotton blue for detecting of dermatophytic elements. Specimens were cultured on sabouraud glucose agar and sabouraud glucose agar with chloramphenicol (0.005%, Merck Chemical Co., Darmstadt, Germany) and cyclohexamide (0.04%, Sigma Chemical Co., St. Louis, USA), and incubated at two different temperatures, 30°C and 37°C, for one month. The cultures without any growth discarded as negative cultures.

In order to identify isolated dermatophytes, dermatophyte test medium (DTM) and nutrient agar (Merck Chemical Co., Darmstadt, Germany) were used, as well.

The results were assessed using Student's t test and the  $\chi^2$  test where appropriate.

## Results

In this study, the cattle were more than one years

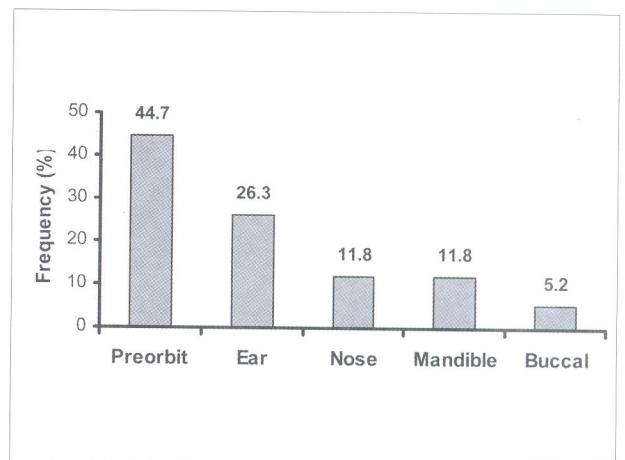


Figure 2. Distribution of dermatophyte lesions based on different sites of cattle head.

old age, in which 14 cases were male (20%) and the others were female (80%). The mean of duration of infections was 2 weeks. Of 70 animals, 43 were symptomatic and 27 had no clinical signs. The results of mycological studies were as follow:

- Positive direct microscopic examination: 13 cases (30/2%).
- Positive culture: 5 cases (11/6%).
- Positive direct microscopic examination and culture: 25 cases (58/1%).

The only etiologic agent of the infection was *T. verrucosum*.

As shown in Fig. 1, the most lesions were localized on the head and neck areas. There was significant relation between the frequency of the head and neck lesions. Also, significant differences were observed between head lesions and other sites.

Fig. 2 showed that the most distribution of lesions on head were observed on preorbital (34 cases: 44.7%), ear (20 cases: 26/3%), mandible (9 cases: 11.84%), nasal (9 cases: 11.84%) and buccal (4 cases: 5.26%) areas, respectively.

## Discussion

Dermatophytosis is a common skin infection in intensive breeding system of ruminants in worldwide (Khosravi and Mahmoudi, 2003). It has seasonally related prevalence especially in autumn and winter (Cabanes, Abarca and Bragulat, 1997; Stenwig, 1985). Our study showed that cattle dermatophytosis was prevalent in winter. Age is an important factor in



incidence of dermatophytosis (Rippon, 1988). Despite of other findings, adult cattle were also infected in our study. The certain cause of this matter is uncertain, but it seems that *T. verrucosum* isolated in our study has probable different virulence in compare with other isolates (Khosravi and Abedian, 1998). On the other study carried out in Iran, the morphology of *T. verrucosum* isolated from camels, goats and sheep was different from that of the cattle isolates (Khosravi and Mahmoudi, 2003).

In the present study, *T. verrucosum* isolates were slow growing, heaped, and folded, with a yellowish surface. Some similarities were observed between our isolates and the other mentioned isolates, which approved to have high virulence (Khosravi and Abedian, 1998). Based on the other findings, the lesions were mainly localized on the head and neck (Vancutsem and Rochett, 1991; Khosravi and Mahmoudi, 2003). The most lesions on the head were observed around the eyes and ears. It is speculated that because of folded and thinner skin of eyes and ears, dermatophytes conidia can colonize readily and exist for a long time on these areys. So, the infected animals were repeatedly transferred the fungal elements to environment and other animals in stable, which had close contact with together. According to different investigators findings in Iran, dermatophytosis in cattle and sheep, with *T. verrucosum* agent, has a high prevalence (Khosravi, Kordbacheh and Bokae 1994).

In rural areas, people who have close contact with infected animals are affected by this organism (Pier *et al.*, 1991; Chatterjee and Gupta, 1980; Khosravi, Aghamirian and Mahmoudi, 1994). For this reason, we are going to plan a program to provide a suitable *T. verrucosum* antigenic complex as vaccine for immunizing cattle against dermatophytosis into the future.

### Acknowledgements

This work was supported by the Research Council of the University of Tehran.

### References

1. Cabanes, F.J., Abarca, M.L., Bragulat, M. (1997) Dermatophytes isolated from domestic animals in Barcelona, Spain. *Mycopathol.* 137: 107-113.
2. Chatterjee, A., Gupta, D.N. (1980) Some epidemiological aspects of zoophilic dermatophytosis in India. *J. Zoonoses.* 7: 19-33.
3. Khosravi, A.R., Abedian, Z. (1998) The electrophoretic protein pattern of *Trichophyton verrucosum* varieties. *J. Vet. Res.* 53: 4-11.
4. Khosravi, A.R., Aghamirian, M.R., Mahmoudi, M. (1994) Dermatophytosis in Iran. *Mycoses.* 37:43-8.
5. Khosravi, A.R., Kordbacheh, P., Bokae, S. (1994) An epidemiological approach to the zoophilic dermatophytosis in Iran. *M. J. I. R. I.* 7:253 - 257.
6. Khosravi, A.R., Mahmoudi, M. (2003) Dermatophytoses isolated from domestic animals in Iran. *Mycoses.* 46: 222- 225.
7. Mackenzie, D.W.R., Loeffler, W., Mantovani, A., Fujikura, T. (1986) Guidelines for Diagnosis, Prevention and Control of Dermatophytoses in Man and Animals. Geneva: World Health Organization.
8. Moghadami, M., Emami, M. (1986) Tinea capitis in Iran. *Iranian J. Publ. Health.* 15: 60-70.
9. Pier, A.C., Smith, J.M.B, Alexiou, H., Ellis, D.H., Lunda, A. and Pritchard, R.C. (1991) Animal ring worm its-etiology, Public health significance and control. *J. Med. Vet. Mycol.* 29: 285-92.
10. Rippon, J.W. (1988) Dermatophytosis and Dermatormycosis in: Rippon J.W., (2<sup>nd</sup>Ed). *Medical Mycology, the pathogenic fungi and the pathogenic Actinomycetes.* Philadelphia: W. B, New York.
11. Stenwig, H. (1985) Isolation of dermatophytes from domestic animals in Norway. *Nord. Vet. Med.* 37:161-169.
12. Vancutsem, J., Rochett, F. (1991) *Mycoses in domestic animals.* Janssen Research Foundation, (1<sup>st</sup> Ed), pp. 49.



## تظاهر ضایعات در ماتوفیتی بر روی نواحی مختلف بدن گاوهای بالغ

علیرضا خسروی<sup>۱\*</sup>، حجت‌اله شکری<sup>۱</sup>، تقی تقی پور بازرگانی<sup>۲</sup>، رامک یحیی رعیت<sup>۱</sup>، مریم قیاسی<sup>۱</sup>

(۱) مرکز تحقیقات قارچ‌شناسی دانشکده دامپزشکی دانشگاه تهران، تهران - ایران.

(۲) گروه علوم درمانگاهی دانشکده دامپزشکی دانشگاه تهران، تهران - ایران.

(دریافت مقاله: ۲۷ دی ماه ۱۳۸۵، پذیرش نهایی: ۲۲ آبان ماه ۱۳۸۶)

### چکیده

هفتاد گاو مشکوک به بیماری در ماتوفیتوزیس بین فروردین و خرداد سال ۱۳۸۲ معاینه شدند. نمونه‌ها با روش تراشه برداری از ضایعات مختلف برداشت شدند. آزمایش میکروسکوپی مستقیم و کشت انجام شدند. میانگین دوره عفونت ۲ هفته بود. چهل و سه مورد علائم بالینی مثبت در ماتوفیتوزیس نشان داده‌اند و ۲۳ مورد فاقد علائم بالینی بودند. عامل بیماری تنها تریکوفایتون وروکوزوم بود. یک ارتباط معنی‌داری بین فراوانی ضایعات سر و گردن و سایر نواحی مشاهده شد. تفاوت معنی‌داری بین فراوانی ضایعات سر و سایر نواحی بدن وجود داشت. با توجه به اینکه عفونت‌های در ماتوفیتی در انسان به کرات در ایران گزارش شده‌اند، لازم است یک برنامه پیشگیرانه مانند کاربرد واکسن موثر بر علیه در ماتوفیتوزیس در آینده طراحی شود.

واژه‌های کلیدی: در ماتوفیتوزیس، تریکوفایتون وروکوزوم، گاو.

