

# The study of arterial supply of the carpal joint in one-humped camel (*Camelus dromedrus*)

Sajjadian, M.<sup>1</sup>, Nazem, M.N.<sup>2\*</sup>, Radmehr, B.<sup>3</sup>

<sup>1</sup>Department of Basic Sciences, Faculty of Veterinary Medicine, Shahid Bahonar University of Kerman, Kerman, Iran

<sup>2</sup>Department of Basic Sciences, Faculty of Veterinary Medicine, Shahid Bahonar University of Kerman, Kerman, Iran

<sup>3</sup>Department of Basic Sciences, Faculty of Veterinary Medicine, Oloum tahghighat, Tehran, Iran.

## Key words:

*Dromedrus camel*, carpal joint, radial artery, median artery, caudal interosseous artery

## Correspondence

Nazem, M.N.

Department of Basic Sciences,  
Faculty of Veterinary Medicine,  
Shahid Bahonar University of  
Kerman, Kerman, Iran

Tel: +98(343) 3222047

Fax: +98(343) 3222047

Email: nnazem@mail.uk.ac.ir

Received: 26 August 2014

Accepted: 19 November 2014

## Abstract:

**BACKGROUND:** There is little information about blood supply of the carpal joint in one-humped camel, while there is extensive data about cow and equine species. In order to perform surgeries and diagnostic techniques in carpal region, information about the elements of the joint such as its arteries is necessary. **OBJECTIVES:** This study aims at describing the origins, arrangements, and branches of the arterial supply of the carpal joint of the adult one-humped camel (*Camelus dromedarius*). **METHODS:** Twelve left forelimbs of camelus *Dromedrus* without any lameness history were divided into 3 equal groups randomly. The brachial artery, before the elbow joint, was injected with warm water containing red gelatin, red latex solution, and rodopas resin solution separately; then, the arterial supply of the carpal joint was studied. **RESULTS:** The results showed that the radial, median, and caudal interosseous arteries and their branches supplied the carpal joint. (Supplied the carpal joint) **CONCLUSIONS:** Our findings showed that radial artery and its branches such as dorsal and palmar carpal branches were the most important arteries that supply the carpal joint. Median and caudal interosseous arteries support supplying this joint too but the arterial branches supplying the carpal joint in the Bactrian camel are from the radial artery and dorsal interosseous antebrachium branches. In the cow, the common interosseous, median, collateral ulnar and radial arteries give off branches to supply the carpal joint while common interosseous, median, transverse cubital and radial arteries give off branches to supply the this joint in the horse.

## Introduction

Carpal region is composed of several bones and their supportive structures, nerves and vessels. According to the importance of healthy of the forelimb, the purpose of this study was

to describe the anatomy of the arterial supply of the carpal joint in one-humped camel and comparison results with cow and equine ones.

Some researchers have been studied anatomical structures of bones (Soroori et al., 2007), tendons (Soroori et al., 2011) and digits

/ foot pad (Badawy, 2011) of the forelimb in one-humped camel by means different methods.

The arterial supply of the forelimb of Bactrian camel has been studied previously (Jain et al., 1992; Jian-Lin et al., 1994; Jian-Lin et al.; 1998, Jian-Lin et al., 2000). Moreover arterial supply to the scapular, brachial and antebrachial regions of the llama has studied too (Arzone et al., 1995). Information about the arterial supply to the carpal joint in the one-humped camel (*Camelus dromedrus*) is lesser and also is rare comparing with than other species. Current study was conducted to describe the origins, arrangements and branches of the arterial supply of the carpal joint in the adult one-humped camel (*Camelus dromedarius*), where it gives anatomical information for researches and surgeons in the field of camel medicine.

## **Materials and Methods**

Twelve left forelimbs of one-humped camel were divided in 3 equal groups. The samples were selected without regard to sex. Forelimbs were cut on the top of the elbow joint and the entrance of the brachial artery in the distal part of the forelimb was exposed to injecting fluid.

In the first group, warm water containing red gelatin was infusion through into the brachial artery by syringe. Consequently skin of the forelimbs was removed and limbs were transferred to the 10% formalin solution. After ten days, arteries of the carpal joint were carefully described. This method helped to finding small arteries in this region.

Process of the second group was similar to the first group but in this group, red latex solution was injected. Recent method allowed dissecting arteries easier than before technique but unlike it, couldn't expose small arteries.

Rodopas resine solution was similarly injected. The samples were placed in cold water for a week. Then samples were placed in HCl acid (Merk, KgaA, German) for 2 days and

after that carpal arteries were studied. In this method, muscles, nerves and other soft tissues around the arteries were removed by acid.

Finally revealed anatomical structures were vigilantly explored.

## **Results**

Camel carpal arterial branches were spread plexus under the dorsal carpal ligament. Several thin arteries of this plexus were supplied the carpal bones except the accessory carpal bone. Also some of these arteries entered the carpal capsules from the dorsal inter carpal ligaments and supplied them. Palmar arterial plexus placed under the palmar carpal ligament but didn't as broad as the dorsal carpal plexus. Also some arteries from this plexus were supplied the palmar capsule and ligaments of the palmar surface (Fig. 1).

Distal forelimb arteries arrived from the brachial artery.

The transverse cubital artery, collateral ulnar artery and common interosseous artery were derived from the brachial artery but didn't achieve to the carpal joint and thus couldn't supply this joint. The Cranial interosseous artery that was given off by the common interosseous artery didn't arrive to the carpal joint and thus couldn't supply this joint too (Fig. 1,3).

The brachial artery became the median artery at the end of the distal fourth of the brachium after detachment of common interosseous artery. Median artery was the most artery of the antebrachium that was continued ventrally near the median vein and median nerve to the carpal joint. At the beginning, it passed ventrally between the flexor carpi radialis and radial head of the flexor digitorum profundus muscles at the medial border of the radius. At the palmar surface, it continued ventrally under the flexor carpi radialis muscle (next to the humeral and radial heads of the flexor digitorum profundus muscle) to the carpal joint. Median artery gave off several branches before arriv-

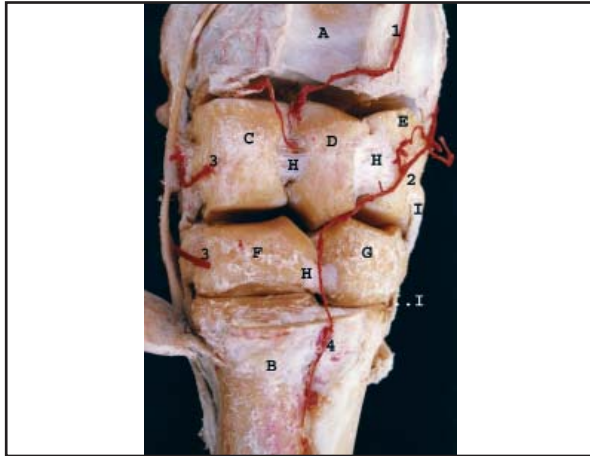


Figure 1. Dorsal carpal arteries and ligaments (dorsal arterial plexus is seen) (carpal joint capsule is removed). A) Radial bone. B) Metacarpal bone. C) Radial carpal bone. D) Intermediate carpal bone. E) Ulnar carpal bone. F) 3rd carpal bone. G) 4th carpal bone. H) Dorsal intercarpal bone ligaments. I) Deep part of collateral ligament. 1) Interosseous artery. 2) Dorsal carpal branch of palmar branch of radial artery. 3) Dorsal carpal branches of radial artery. 4) Dorsal metacarpal artery.

ing to the carpal joint. These branches were supplied the muscles surrounding them. Then this artery gave off radial artery (the largest branch of this artery) at the final third of the radius. It extended ventrally between ligaments of the flexor digitorum superficial and flexor digitorum profundus muscles at the palmar surface. It passed from palmar part of carpal joint while surrounding by ligaments of the flexor digitorum superficial and flexor digitorum profundus muscles, median nerve and flexor retinaculum. It joined to palmar branch of the radial artery at palmar surface of metacarp and created the superficial palmar arc (Fig. 2,3).

Radial artery, the most branch of the median artery, was the most artery that supplied the carpal joint which derived from median artery adjacent to ligament of flexor carpi radialis muscle at the final third of caudal surface of radius. This artery was passed under the flexor carpi radialis muscle near the humeral head of flexor digitorum superficialis and then changed its way to distal interosseous space and finally divided into two branches at the top of the distal interosseous space near the flexor digitorum

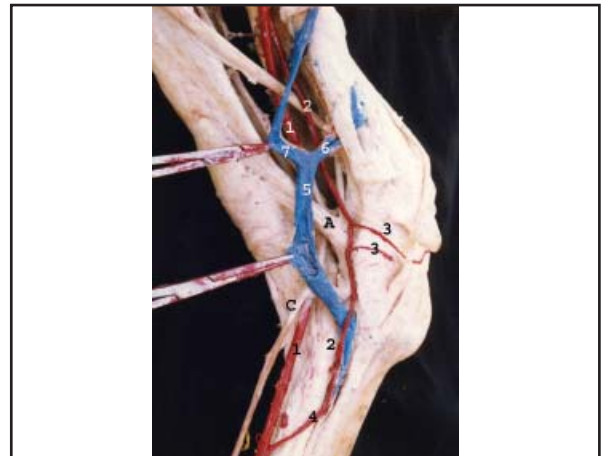


Figure 2. Medial surface of the carpal joint. A) Flexor retinaculum. B) Tendon of flexor carpi radialis muscle. C) Median palmar nerve. 1) Median artery. 2) Radial artery. 3) Dorsal carpal branches of radial artery. 4) Superficial palmar branch of radial artery. 5) Radial vein. 6) Cephalic vein. 7) Median vein.

profundus muscle: the thick branch was named palmar branch of radial artery and thin branch that was continuation of radial artery (Fig. 3).

Palmar branch of radial artery with palmar branch of radial vein and lateral palmar nerve passed between ligaments of deep digital flexor muscle at the caudal surface of the antebrachium over the palmar ligament and entered the carpal canal at the medial surface of accessory carpal bone. Palmar branch of radial artery was divided into superficial and deep branches after crossing from carpal canal. Superficial branch was joined to medial artery over the suspensory ligament next to the fetlock and was accompanied in superficial palmar arc. Deep branch was passed between the suspensory ligament and metacarpal bone and was joined to deep palmar branch of radial artery and formed deep palmar arc. Deep palmar branch was given off palmar metacarpal artery (Fig. 3). Palmar branch of radial artery gave off several branches: interosseous, dorsal and palmar carpal branches.

Interosseous artery of palmar branch of radial artery was resulting from palmar branch of radial artery near the distal interosseous space and after joining to the caudal interosseous artery was entered to distal interosseous space.

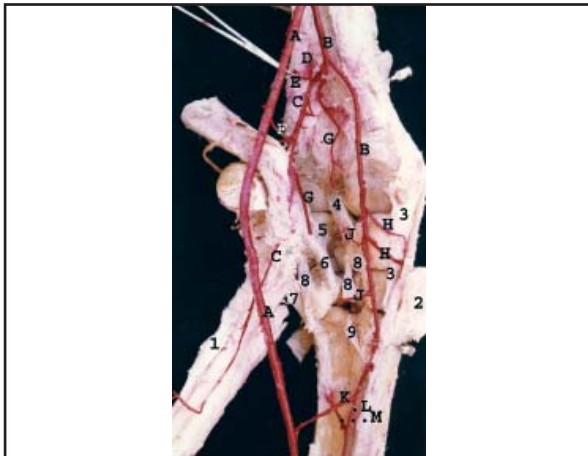


Figure 3. Palmar carpal arteries and ligaments of the carpal joint. A) Median artery. B) Radial artery. C) Palmar branch of median artery. D) Interosseous artery. E) Caudal interosseous artery. F) Dorsal carpal branch of palmar branch of radial artery. G) Palmar carpal branches of palmar branch of radial artery. H) Dorsal carpal branches of radial artery. I) Palmar carpal branches of radial artery. J) Superficial palmar branch of radial artery. K) Deep palmar branch of radial artery. L) Deep palmar arc. 1) Suspensory ligament. 2) Superficial part of medial collateral ligament. 3) Deep parts of medial collateral ligament. 4) Palmar radiocarpal ligament. 5) Accessorioulnar carpal ligament. 6) Accessorioquartal ligament. 7) Accessoriometacarpal ligament. 8) Palmar intercarpal ligaments. 9) Palmar carpometacarpal ligaments.

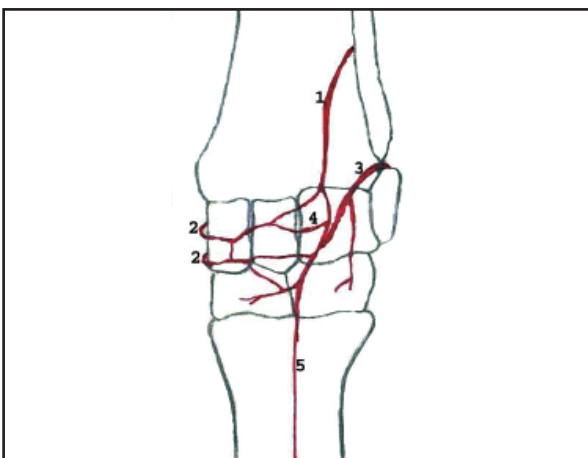


Figure 5. Schematically plan of arterial supply of the dorsal carpal joint. 1) Interosseous artery. 2) Dorsal carpal branch of radial artery. 3) Dorsal carpal branch of palmar branch of radial artery. 4) Dorsal carpal arterial plexus. 5) Dorsal metacarpal arteries.

This artery continued at the dorsal surface of the radius, between the ligaments of extensor digitorum communis and extensor carpi radialis muscles, to dorsal surface of carpal joint.

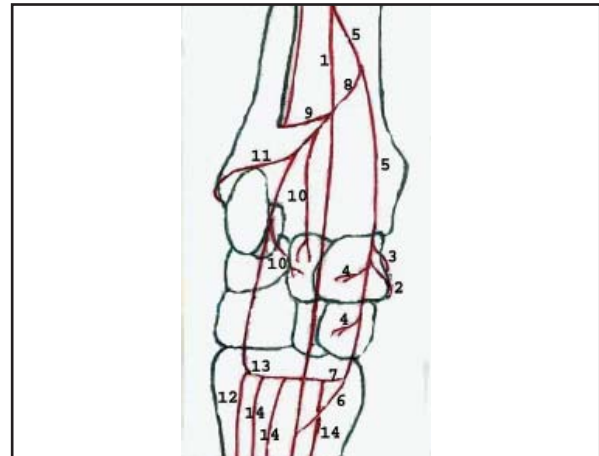


Figure 4. Schematically plan of arterial supply of the palmar carpal joint. 1) Median artery. 2) Dorsal carpal branch of radial artery. 3) Palmar carpal branch of radial artery. 4) Radial artery. 5) Superficial palmar branch of radial artery. 6) Deep palmar branch of radial artery. 7) Palmar branch of radial artery. 8) Interosseous artery. 9) Palmar carpal branch of palmar branch. 10) Dorsal carpal branch of palmar branch. 11) Superficial branch of palmar branch. 12) Deep branch of palmar branch. 13) Palmar metacarpal arteries. 14) Collateral radial artery.

Interosseous artery gave off some branches to supply the extensor digitorum communis and extensor carpi radialis muscles and connected to the dorsal carpal artery after the extensor carpi obliquus muscle (Fig. 1,3).

Dorsal carpal branch of palmar branch of radial artery was given off from radial artery before entering to carpal canal and was passed over the accessory ulnar ligament immediately. This arterial branch was turned round accessory ulnar ligament to arrive dorsal surface of carpal joint on the dorsal carpal ligament near the lateral surface of accessory carpal bone and was sent some branches to supply this carpal bone. This artery joined to the dorsal carpal arterial plexus finally (Fig. 1).

Palmar carpal branches of palmar branch of radial artery included 2 or 3 branches that arose from radial artery in the carpal canal and were joined to palmar carpal arterial plexus (Fig. 1).

After giving off this recently branch, radial artery continued adjacent the ligament of flexor carpi radialis muscle and passed from flexor retinaculum at the palmar surface of carpal joint and then divided into superficial



palmar and deep palmar branches immediately after palmar carpal region. Superficial palmar branch connected to median artery at the proximal of the first third of metacarpal bone and corporate in superficial palmar arc formation. Deep palmar branch passed between suspensory ligament and metacarpal bone and joined to deep branch of palmar branch of radial artery to form deep palmar arc (Fig. 2,3).

Lateral branches of radial artery were dorsal and palmar carpal branches. Dorsal carpal branches of radial artery were derived from radial artery at the flexor retinaculum and were passed between the deep and superficial parts of medial carpal collateral ligaments and were joined to dorsal carpal plexus. Palmar carpal branches of radial artery were given off by the radial artery at the flexor retinaculum too and were joined to palmar carpal artery (Fig. 3).

Schematic plan of arterial supply of the carpal joint has been shown in figures 5 and 6 (Fig. 4,5).

Arterial supply of the carpal joint are shown in the figures 5 and 6 schematically.

## Discussion

Several studies were investigated the forelimb arteries in the camel (Smuth et al., 1987; Jian-Lin et al., 1994; Jian-Lin et al., 1998; Jian-Lin et al., 2000.). Smuts et al. (Smuth et al., 1987) reported that common interosseous, median and radial arteries are supply to the carpal joint, while our findings indicate that the caudal interosseous, median and radial arteries supply the carpal joint.

In addition we showed that arterial plexus of the carpal joint in one – humped camel, similar to the horse and cow ones (Budras et al., 2009; Dyce et al., 1996; Nickel et al., 1981) was below the dorsal and palmar carpal ligaments and composed of several arteries. Like to the horse, cow (Budras et al., 2009; Getty, 1975; Nickel et al., 1981) and Bactrian camel (Jian-Lin et al., 2000), dorsal carpal plexus in

one – humped camel was more developed than palmar arterial plexus.

Distal branches of brachial artery in the one – humped camel were transverse cubital, collateral ulnar and interosseous arteries, which have been reported with other researchers in dromedrus, Bactrian camel and llama (Arzone et al., 1995; Bego, 1960; Jain et al., 1992; Smuth et al., 1987; Jian-Lin et al., 2000). In our samples, transverse cubital artery was derived from the brachial artery before the collateral ulnar artery, while it originates from the brachial artery after the collateral ulnar artery in the horse and cow (Getty, 1975; Nickel et al., 1981). Our results about transverse cubital artery were in agreement with Bactrian camel anatomical findings (Jian-Lin et al., 2000).

Brachial artery was became median artery after detachment of the common interosseous artery. This artery was the most important artery of antebrachial and was continued to carpal joint. In this way it gave off some branches that named deep antebrachial arteries. This artery was anatomically similar to the Bactrian camel (Jian-Lin et al., 2000), cow (Dyce et al., 1996; Getty, 1975; Nickel et al., 1981) and horse (Budras et al., 2009; Dyce et al., 1996; Getty, 1975; Nickel et al., 1981) ones.

Median artery continued about the final third of antebrachial and then gave off radial artery. Radial artery was the only branch of the median artery at the top of the carpal joint in the camel. It was like to cow ones (Dyce et al., 1996; Getty, 1975; Nickel et al., 1981), while it gives off three branches in the horse (Budras et al., 2009; Nickel et al., 1981; Getty, 1975). This artery was passed from carpal canal to metacarpal region after detachment the radial artery. Findings in Bactrian camel have shown that this artery doesn't participate in supplying the carpal joint (Jian-Lin et al., 2000).

Radial artery was the most important arterial supply to the carpal joint but its branches had basic differences with its counterparts in horse and cow (Budras et al., 2009; Dyce

et al., 1996; Getty, 1975; Nickel et al., 1981). In the cow the region of origin is located in the proximal but in the horse is in the distal third of the lower humerus. In the horse there is the small dorsal radial artery at the first and then, immediately before the elbow joint, radial artery. Except in the horse, the radial artery runs caudomedially to the median artery along the caudomedial edge of the radius. Immediately proximal to the carpus it gives rise to the dorsal carpal artery which contributes to the formation of the dorsal and palmar rete carpal which goes to the palmar articular network. The radial artery then reaches the flexor retinaculum in a palmar position. In the horse the dorsal and palmar carpal rete do not come off the radial artery but arise by proximal radial artery. Therefore the radial artery, which arises far distally, divides immediately into the deep and superficial palmar branches. This artery doesn't participate in supplying the carpal joint in Bactrian camel (Jian-Lin et al., 2000).

In the one - humped camel like to the Bactrian camel (Jian-Lin et al., 2000), the palmar branch was derived from the radial artery, while it is a branch of median artery in the horse and cow (Getty, 1975, Nickel et al., 1981). Palmar branch of radial artery in the camel was continued to lateral border of the carpal joint and was gave off interosseous artery at the distal interosseous space. These results were similar to findings in Bactrian camel and llama (Arzone et al., 1995; Jian-Lin et al., 2000).

Interosseous artery joins to the dorsal carpal artery but doesn't supply the carpal joint in Bactrian camel (Jian-Lin et al., 2000). This artery wasn't detected in the horse (Budras et al., 2009; Nickel et al., 1981) while it is a branch of cranial interosseous artery in the cow (Getty, 1975; Nickel et al., 1981).

Common interosseous artery was the last branch of the brachial artery which stems from it at the dorsal common interosseous space. According to our findings, this artery doesn't supply the carpal joint. Smuts et al. (Smuth et

al., 1987) have reported that common interosseous supplies the carpal joint.

Some researchers have reported that collateral radial artery is the last branch of the brachial artery before the common interosseous artery (Jain et al., 1992), but we showed that common interosseous was the last branch of the brachial artery. It was similar to the cow and horse ones (Budras et al., 2009; Dyce et al., 1996; Getty, 1975; Nickel et al., 1981). Branches of common interosseous were cranial and caudal interosseous arteries that were similar to other studies in Dromedarius (Bego, 1960; Jain et al., 1992; Smuth et al., 1987) and Bactrian camels (Jian-Lin et al., 2000). In some studies collateral radial artery was known as a branch of the common interosseous artery (Jain et al., 1992).

We showed that cranial interosseous artery was short and was passed under the extensor digitrum communis muscle but didn't arrive to carpal joint, while other researchers have reported this artery continues above the carpal joint and supplies it (Jain et al., 1992; Smuth et al., 1987). Jian-Lin has stated that this branch supplies the carpal joint in Bactrian camel (Jian-Lin et al., 2000), while Arzone didn't detect this artery in llama (Arzone et al., 1995).

Our results indicate that caudal interosseous artery was the only branch of the common interosseous artery. This artery was relatively a thick artery at the caudal surface of the radial bone that continued above the distal interosseous space and joined to palmar branch of interosseous artery of radial artery. Other researchers reported that this artery divides into dorsal and palmar branches above the carpal joint and finally joins to dorsal and palmar carpal plexuses finally (Jain et al., 1992; Smuth et al., 1987). Arzone stated that this artery is short and can't supply the carpal joint in llama (Arzone et al., 1995). There is no report about supplying carpal joint by caudal interosseous artery in the Bactrian camel (Jian-Lin et al., 2000).

Similar to the Bactrian camel (Jian-Lin et al., 2000) and llama (Arzone et al., 1995), Palmar carpal artery gave off dorsal carpal branch before entering the carpal canal. This branch wasn't reported in the horse and cow (Getty, 1975; Nickel et al., 1981). Palmar carpal branch gave off several branches in the carpal canal and finally joined to palmar carpal arterial plexus. These branches weren't reported in the horse and cow (Dyce et al., 1996; Getty, 1975; Smuth et al., 1987). The continuation of palmar branch was similar to the ones in horse (Budras et al., 2009, Getty, 1975; Nickel et al., 1981), cow (Getty, 1975; Nickel et al., 1981) and was divided to superficial and deep branches.

Continuation of radial artery after the palmar branch was similar to ones in the horse, cow and Bactrian camel (Dyce et al., 1996; Getty, 1975; Jian-Lin et al., 2000). It was passed from medial aspect of the flexor retinaculum and gave off some branches to dorsal and palmar carpal arterial plexus. These results are similar to the ones in cow (Nickel et al., 1981) and Bactrian camel (Jian-Lin et al., 2000). Radial artery doesn't have any branch during passage on the carpal joint in the horse (Dyce et al., 1996; Getty, 1975; Nickel et al., 1981). Radial artery positioned at the proximal extremity of the metacarpal bones after passing from the carpal canal. It divided to superficial and deep deep palmar branches in horse (Budras et al., 2009; Dyce et al., 1996; Getty, 1975; Nickel et al., 1981).

Our findings showed that radial artery and its branches, median and caudal interosseous arteries supply this joint but the arteries supply the carpal joint in the Bactrian camel are radial artery and its branches and the dorsal interosseous antebrachium branches (Jian-Lin et al., 2000). In the cow, the common interosseous, median, collateral ulnar and radial arteries give off branches to supply the carpal joint but the common interosseous, median, transverse cubital and radial arteries give off branches to

supply the carpal joint in the horse (Budras et al., 2009; Dyce et al., 1996; Getty, 1975; Nickel et al., 1981).

## Acknowledgments

This research was financially supported by the research council of Shahid Bahonar University of Kerman.

## References

1. Arzone, C.A., Calaudi, P., Casalonga, O., Valdes, V.A.(1995) Arterial irrigation of the scapular, brachial and antebrachial regions of the llama. *Excreta camelida*. 2: 14-20.
2. Badawy Adel, M. (2011) Computed tomographic anatomy of the fore foot in one-humped camel (*Camelus dromedrus*). *Glob Vet*. 6: 417-423.
3. Bego, U. (1960) Comparative anatomy of blood supply and nerves of the fore leg in the camel, llama, giraffe and cattle. *Acta Anat*. 42: 261.
4. Budras Klaus – Dieter, Sack, W.O., Rock, S. (2009) *Anatomy of the Horse*. (5<sup>th</sup> ed.) Schlutersche. Frankfurt, Germany. p. 8-11.
5. Dyce, K.M., Sack, W.D., Wensing, C.J.G. (1996) *Text Book of Veterinary Anatomy*. (2<sup>nd</sup> ed.) W.B.Saunders company. Philadelphia, USA.
6. Getty, R. (1975) *Sisson and Grossman's. The Anatomy of the Domestic Animals*. (5<sup>th</sup> ed.) W.B.Saunders company. Philadelphia, USA.
7. Jain, R.K., Dhingra, L.D. (1992) The brachial artery of camel. *Indian J Anim Sci*. 63: 38-41.
8. Jian-Lin Wang, Cui-Sheng, Gen-Xuan Wang, Hai-Yan, Li. (2000) The arterial supply of the carpal joint in the Bactrian camel (*Camelus bactrianus*). *Vet Res Commun*. 24: 75-84.
9. Jian-Lin Wang, Cui-Sheng, Zheng-Ming Xie. (1998) The arterial supply of the metacarpophalangeal joint in the Bactrian camel (*Camelus bactrianus*). *Vet Res Commun*. 22: 365-371.

10. Jian-Lin Wang, Zheng-Ming, Xie. (1994) Arterial supply of the shoulder joint in the Bactrian camel (*Camelus bactrianus*). J Camel Pract Res. 2: 71-74.
11. Nickel, R., Schummer, A., Seiferle, E. (1981) The anatomy of the domestic animals. Vol. 3. Verlag Paul Parey. Berlin-Humburg, Germany.
12. Smuts, M.S., Bezuidenhout, A.J. (1987) Anatomy of the Dromedary. (1<sup>st</sup> ed.) Clarendon Press, Oxford, UK.
13. Soroori, S., Veshkini, A., Dehghan, M., Farhadian, O. (2007) Radiographic assessment of bone cortex to bone diameter ratio of manus and pes in camel. Iranian journal of veterinary surgery (IJVS). 2: 7-12.
14. Soroori, S., Masoudifard, M., Vajhi, A.R., Rostami, A., Salimi, M. (2011) Ultrasonography study of tendons and ligaments of metacarpal region in the camel (*Camelus dromedarius*). Int J Vet Res (University of Tehran). 5: 85-88.