

## Vaginal fibrosarcoma in cow (A case report)

Hamali, H.<sup>1\*</sup>; Ashrafihelan, J.<sup>2</sup>

<sup>1</sup>Department of Clinical Sciences, Faculty of Veterinary Medicine, University of Tabriz, Tabriz, Iran. <sup>2</sup>Department of Pathobiology, Faculty of Veterinary Medicine, University of Tabriz, Tabriz, Iran.

### Key Words:

Fibrosarcoma; tumor; cow; vagina; immunohistochemistry.

### Correspondence

Hamali, H.,  
Department of Clinical Sciences,  
Faculty of Veterinary Medicine,  
University of Tabriz, Tabriz, Iran  
Tel: +98(914)1145575  
Fax: +98(411)3357834  
Email: hamali@tabrizu.ac.ir

Received: 11 April 2009

Accepted: 10 August 2010

### Abstract

A five-year-old Holstein cow with a history of vaginal prolapse was admitted to the Large Animal Clinic, Faculty of Veterinary Medicine, University of Tabriz. According to the owner, she had a 5-month history of vaginal prolapse and frequent sanguineous discharge from the vagina. Appetite was normal and its last parturition was two months ago. Clinical examination revealed a tumor like mass that attached to the vaginal roof and partly protruded through the vagina without any vaginal prolapse. After epidural anesthesia, the mass was surgically removed with some of the surrounding tissue. The dimensions of the mass were  $5.2 \times 4 \times 3.4$  cm. Macroscopically, it was relatively well circumscribed with a lobulated and ulcerated surface. In cut section, the mass was homogenously creamy in color. There were no foci of necrosis or hemorrhage. Microscopically, the growth was composed of spindle-shaped fibroblastic type tumor cells that formed interlacing and intersecting bundles. The neoplastic cells showed pleomorphism, karyomegaly and slight nuclear hyperchromatism. The mitotic index was less than five. Based on the site, biological behavior, immunohistochemistry results, macroscopic and microscopic characteristics, the mass was diagnosed as a well-differentiated fibrosarcoma. This is the first report of cow vaginal fibrosarcoma from Iran.

### Introduction

Tumors of the genital tract in cattle have been reported from different countries of the world (Yeruham *et al.*, 1999; Anderson *et al.*, 1969; McEntee *et al.*, 1976; Susaneck 1981). However, reports on bovine fibrosarcoma compared with other tumors of cattle are very rare (Yeruham and Orgad, 1999; Musal *et al.*, 2007; Birgit *et al.*, 2004).

Fibrosarcoma is a type of sarcoma, a malignant tumor of soft tissue that connects, supports or surrounds other structures and organs of the body. They are malignant tumors of fibroblasts that show no other evidence of cell differentiation. Immunohistochemically, fibrosarcoma can be separated from other spindle cell tumors (Maxie, 2007; Meuten, 2004). These tumors are common in dogs and cats and uncommon in other domestic species. Although these can be found in any location of the body, they are unusual mesenchymal tumors of the bovine vagina (Masud, 2007; Maxie, 2007). The most important effect of these tumors on the cattle industry is the increased culling rate due to metastases to the other critical organs, such as the lungs, liver and draining lymph nodes, which in turn causes severe complications (Yeruham *et al.*, 1999).

Vaginal fibroma, fibropapilloma, rhabdomyoma,

leiomyoma and leiomyosarcoma have previously been reported in cattle in our country but there has been no report of vaginal fibrosarcoma from Iran (Sohrabi-Haghdooost *et al.*, 1990; Naghshineh *et al.*, 1991; Sohrabi-Haghdooost, 1991). The purpose of this report was to describe the clinical investigation, gross and histopathological findings, and surgical treatment of a vaginal fibrosarcoma in a cow.

### Case history

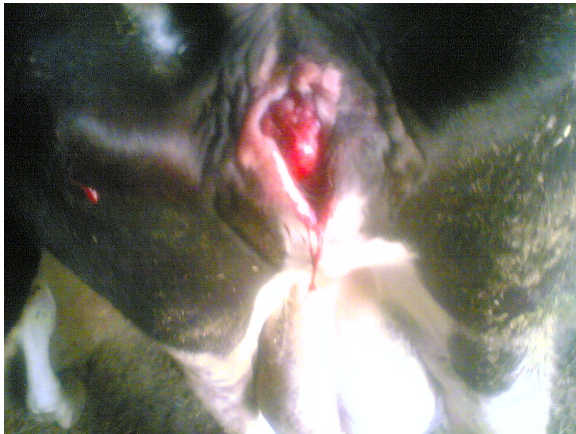#### Clinical findings

A 5-year-old black and white Holstein cow was admitted in the Large Animal Clinic, Faculty of Veterinary Medicine, University of Tabriz, during late spring 2009, due to a 5-month history of vaginal prolapse and a frequent mucosanguineous discharge from the vagina.

Clinical examination revealed no other abnormalities, and its appetite was normal and the last parturition was two months ago. Vaginal examination revealed no evidence of vaginal prolapsed, but a tumor-like vaginal mass was detected that was attached to the vaginal roof and partially protruded through the vagina (Figure 1). The mass was congested. It was hard in consistency with a broad sessile-based and lobulated

appearance that occupied the vaginal lumen. Its mucosal surface was wet, ulcerated and frequently was bled.

Hematological examination of the cow prior to surgical excision showed a mild leukocytosis and anemia. The total WBC count was elevated to  $14.3 \times 10^3 / \mu\text{L}$  and the lymphocyte count were  $7.320 \times 10^3 / \mu\text{L}$ . In order to perform surgical excision, the cow was restrained and anesthetized by the administration of 10 ml of 2% lidocaine (Manufactured by the Pasteur Institute of Iran) into the epidural space. Also, local anesthesia was performed with the infiltration of 20 ml of 2% lidocaine within the vaginal mucosa surrounding the base of the tumor mass. Because local invasion was as evident as finger-like projections of tumor into surrounding tissues, the mass was completely removed with a part of peripheral tissues and the base was cauterized. Postoperative parental antibiotic and local wound healing agents were administered for three and five days, respectively.



**Figure 1:** Protrusion of a large vaginal tumor mass from the vulva in a 5-year-old Holstein cow.

### Pathologic findings

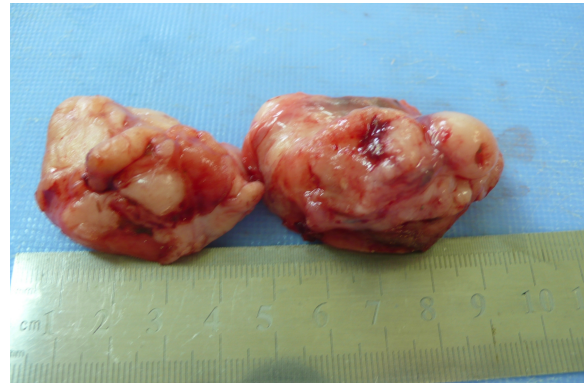
Macroscopically, a hard, solid,  $5.2 \times 4 \times 3.4$  cm firm mass was resected (Figure 2). The mass was relatively circumscribed with a lobulated and ulcerated surface. The cut section was homogeneously creamy in color, with an obvious interwoven fascicular pattern. There were no foci of necrosis or hemorrhage (Figure 3).

Microscopically, the growth was composed of spindle-shaped tumor cells forming interlacing and intersecting bundles. The neoplastic cells were fibroblast-type cells that showed nuclear and cellular pleomorphism, karyomegaly, slightly nuclear hyperchromatism, and loss of polarity (Figure 4). Most of nuclei were elongated to form oval shapes and contained one or more prominent nucleoli. The tumor cells had a scant amount of cytoplasm. The cell boundaries were ill-defined. The nuclear to cytoplasm ratio (N/C) was increased from  $1/4$  to  $1/3$  in normal fibroblasts to  $1/1$  to  $2/1$  in neoplastic cells (Figure 5). Mitotic figures were

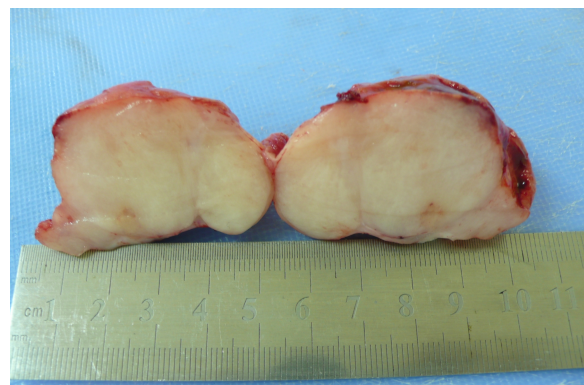
relatively uncommon and the mitotic index (total number of mitotic figures in ten high-power [ $\times 400$ ] fields) was less than five.

Mononuclear and multinucleated tumor giant cells (bizarre cells) with large nuclei and prominent nucleoli were generally seen (Figure 5). Small lymphocytes and plasma cells foci were scattered throughout the tumor. Special staining with Masson's trichrome method showed considerable collagen bundles that were synthesized by tumor cells. The collagen of stroma was pronounced (Figure 6). Immunohistochemical (IHC) staining was used to distinguish the tumor from other spindle cell neoplasms, such as leiomyosarcoma and hemangiosarcoma. An IHC kit (DAKO, Denmark) showed that the tumor was negative for desmin, actin and CD34, which confirmed a connective tissue origin. Such proteins are found in smooth muscle (leiomyocytes) and vascular endothelial cells. Additionally, in contrast to a fibropapilloma, the tumor had no proliferating fibrous tissue with an epithelial covering of variable thickness.

On the basis of the site, IHC staining results, biological behavior, macroscopic and microscopic characteristics, the mass was diagnosed as a well-differentiated fibrosarcoma.

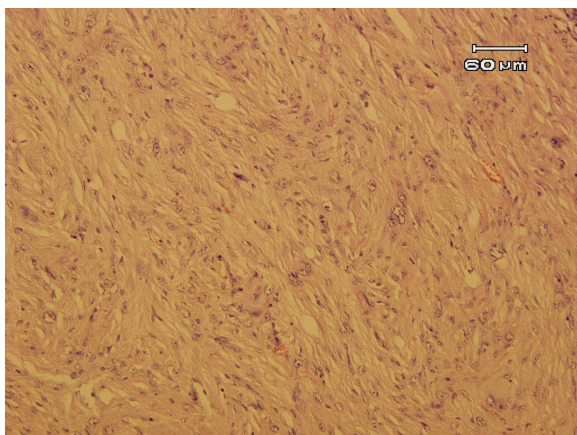


**Figure 2:** A solid, firm vaginal tumor mass with a lobulated and ulcerated surface in a 5-year-old Holstein cow.

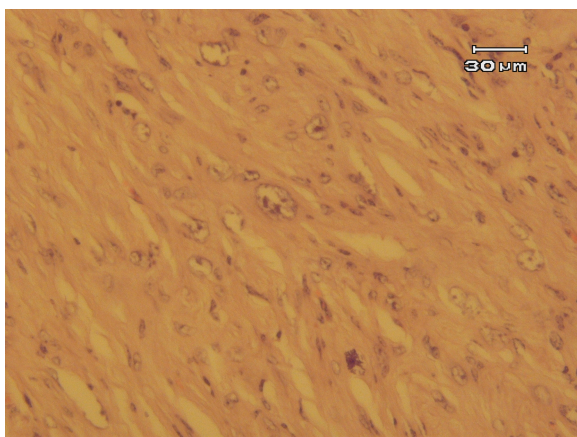


**Figure 3:** Macroscopic view of a solid firm vaginal tumor mass. The cut surface is homogeneously creamy in color with an obvious interwoven fascicular pattern of growth.

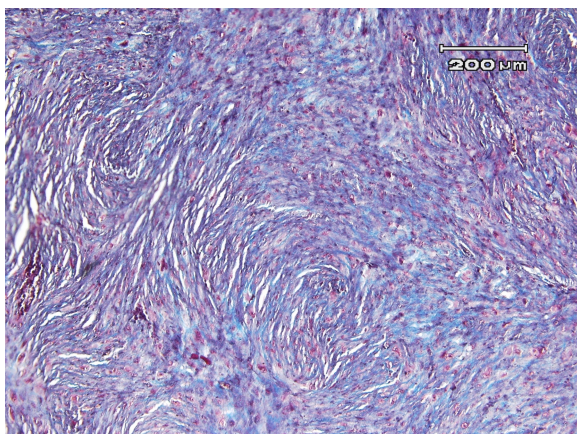




**Figure 4:** Microscopic view of a well-differentiated bovine vaginal fibrosarcoma, showing interlacing bundles of fibroblast-type neoplastic cells, pleomorphism, karyomegaly and bizarre cells (H&E,  $\times 200$ ).



**Figure 5:** Microscopic view of a well-differentiated bovine vaginal fibrosarcoma. The neoplastic cells show marked pleomorphism and karyomegaly. A few mononuclear tumor giant cells (bizarre cells) with large nuclei and prominent nucleoli are seen (H&E,  $\times 400$ ).



**Figure 6:** Microscopic view of a well-differentiated bovine vaginal fibrosarcoma, showing interlacing bundles of fibroblast-type neoplastic cells and considerable collagen bundles that were synthesized by tumor cells. The collagen of stroma is pronounced (Masson's trichrome method,  $\times 100$ ).

## Discussion

Tumors of the vagina and vulva of cattle are not uncommon. They do not directly lead to infertility but may interfere with breeding and parturition, and then can be associated with dystocia, as was seen in our case. They are usually pedunculated and may be removed surgically (Musal, 2007; Noakes *et al.*, 2009). In a study that focused on tumors of the vulva and vaginal in cattle, the most common neoplasms were identified as squamous cell carcinomas (44%), fibromas and fibropapillomas (38%). The most common tumor on the vulva was squamous cell carcinoma (65%), and those in the vagina were mainly connective tissue tumors, including fibromas and fibropapillomas (81%) (Yeruham *et al.*, 1999). However, there are very few reports with regards to vaginal fibrosarcoma in cattle (Yeruham *et al.*, 1999; McEntee *et al.*, 1974; Musal *et al.*, 2007). Fibrosarcomas can be found in any location of the body but they are unusual mesenchymal tumors of the bovine vagina (Musal, 2007).

The present study is the first report from Iran of a vaginal fibrosarcoma in a cow. The mass was successfully removed and on clinical examination, there were no signs of cachexia or other systemic spread of neoplastic disease. The mild anemia that was seen may have been related to the hemorrhagic discharge from the tumor. The mitotic index of this tumor was low. Other retrospective studies have found that only the mitotic index is significant in predicting behavior. In dogs and cats, a mitotic index less than 9 and 5, respectively was associated with greater survival than a mitotic index of  $>9$  and  $>5$ , respectively (Maxie, 2007).

The cow was reexamined after eight months, and no evidence of any tumor tissue development or recurrence could be found at the external surgical site. The cow was pregnant again. At the present time (15 month after surgery), the cow remains alive; therefore, we have no data on possible metastases of the tumor in this cow via postmortem examination.

In conclusion, this study demonstrates that if the vaginal fibrosarcoma is diagnosed in its early stages and removed by an appropriate surgical approach, local recurrence and systemic spread can be prevented, and the prognosis may be satisfactory.

## References

1. Anderson, L.J.; Sandison, A.T. (1969) Tumors of the female genitalia in cattle, sheep and pigs found in a British abattoir survey. *J. Comp. Path.* 79: 53-63
2. Birgit, M.; Kofler, J.; Huber, J. and Schilcher, F. (2004) Neoplasms of the extremities in cattle-clinical findings, surgical treatment and outcome in 10 cases. *Proceedings of the 13<sup>th</sup> International Symposium and 5<sup>th</sup> Conference on Lameness in Ruminants 11<sup>th</sup>-15<sup>th</sup> February 2004, Maribor, Slovenija*, pp: 4-6
3. Maxie, M.G. (2007) Jubb, Kennedy, and Palmer's *Pathology of Domestic Animals*. Academic Press, 5<sup>th</sup>

- edition., Saunders Elsevier, USA. Vol. 2, pp: 764-766
4. McEntee, K.; Nielsen, S.W. (1976) Tumors of the female genital tract. *Bulletin of the World Health Organization*. 53: 217-226.
  5. Meuten, D.J. (2004) *Tumors in domestic animals*. 4<sup>th</sup> edition., Iowa state press, Ames, Iowa, USA. pp: 290-292.
  6. Musal, B.; Ultas, P. and Aydogan, A. (2007) Vaginal fibrosarcoma in a cow. *Irish Vet. J.* 60: 424-425
  7. Naghshineh, R.; Sohrabi-Haghdoost, I. and Mokhber-Dezfuli, M.R. (1991) A retrospective study of the incidence of bovine neoplasms in Iran. *J. Com. Pathol.* 105: 235 -239.
  8. Noakes, D.E.; Parkinson, T.J. and England, G.C.W. (2009) *Arthur's veterinary Reproduction & Obstetrics*. 9<sup>th</sup> edition., Philadelphia, W.B. Saunders. pp: 407.
  9. Sohrabi-Haghdoost, I.; Boloorch, M. and Sasani, F. (1990) Leiomyosarcoma in Vagina of a Heifer (The First Case Report in Iran). *J. Fac. Vet. Med. Univ. Tehran*. 45: 83 -89.
  10. Sohrabi-Haghdoost, I. (1991). *Oncogenesis and Veterinary Oncology*. 1<sup>st</sup> edition, Tehran University publication, No. 2076, pp: 123-125 and 245-250.
  11. Susaneck, S.J. (1981) Tumors of the female reproductive tract. In: *Oncology Notes*. Fort Collins: Comparative Oncology Unit, Colorado State University. pp: 7-11.
  12. Yeruham, I., Perl, S., Orgad, U. and Yakobson, B. (1999). Tumors of the vulva and vagina in cattle - a 10-year survey. *Vet. J.* 158: 237-239.