

Beak necrosis in broiler breeder roosters

Razmyar, J.¹, Dezfoulian, O.², Akbarian, R.¹, Tolou, A.¹, Nikpiran, H.¹, Peighambari, S.M.^{1*}

¹Department of Clinical Sciences. ²Department of Pathology, Faculty of Veterinary Medicine, University of Tehran, Tehran-Iran.

Abstract: Beak lesions were observed in 50-weeks-old broiler breeder roosters reared under a separate sex mash diet feeding, with low in protein and energy for roosters. All roosters kept with hens showed deformities in the upper and lower beak but the lesions were not found in roosters kept separately. Hens' feed troughs had been covered with galvanized wire grids to exclude the males eating from hens' troughs. There was approximately 5% mortality among roosters with the beak lesions. A marked reduction (23%) on hatchability was observed, but no change in egg production occurred. The beak lesions were the major cause of male's culling in the flock. Histopathological examination of the lesions revealed that the epidermis, keratin layer and underlying connective tissue of the beaks were severely affected by necrosis. Bacteriological cultures yielded, mainly, growth of hemolytic *Staphylococcus aureus*, and hematological tests showed a mild increase in the number of the white blood cells. The case reported here appeared to be a management-related problem. These findings have implications for poultry industry. *J.Vet.Res.* 62,2:33-36,2007.

Key words: mash, rooster, beak, broiler, trough.

Introduction

Beak lesions have been reported in broiler breeder flocks previously (1,2,3).

Such lesions causing beak deformities result in weight loss and mortality due to impaired feeding (2). It appears that in breeder flocks, grids used on hens' feed troughs to prevent the roosters access are important predisposing factors that lead to direct or indirect injury of the epidermis (2). Feeding finely ground meals (mash diet) which produces paste in the mouth have also been reported as a predisposing factor (2,3). A gram-positive keratinolytic bacterium has been associated with the beak lesion development and mortality in a flock of 1-year-old broiler breeder hens (4). This report describes the beak necrosis in a naturally affected flock with no oral lesion development.

Case Report

Beak lesions and deformities, at different

stages, were observed in roosters in a 50-weeks-old flock of broiler breeder consisting of 39000 hens and 4200 roosters. Lesions were found in 100% of 3850 roosters kept with hens but were not found in 350 roosters kept separately. According to farm owner, the problem had been started 8 weeks earlier and caused approximately 5% mortality in the flock. The ration used for both sexes in the flock was a mash diet. Apparently, the first case was found at 42 weeks of age showing deformity initially on the base of maxilla and then on mandible leading to the detachment and breaking off the beak.

Our observation found necrotic lesions beneath the nares, which were mostly unilaterally, on the maxilla and on the mandible (Fig. 1). Roosters were unable to take feed and do their sexual activity. Hens' feed troughs had been covered with the galvanized wire grids to exclude the males but they were eager to eat from hens' troughs. The feed material sizes ranged between 2-5 mm. There was a marked reduction (23%) on hatchability but egg production was unchanged.

*Corresponding author's email: mpeigham@ut.ac.ir, Tel: 021-6923510, Fax: 021-6933222



Samples were taken from feed, feeders and from both healthy and affected roosters as well as hens and were submitted for bacteriological and histopathological examinations. Two carcasses and three live roosters were transported to the faculty of veterinary medicine for further examination and sampling. A unilateral groove of necrosis just beneath the nares on the upper beak and complete necrosis of the lower beak (Fig. 1), emaciation and pectoral muscle atrophy were evident in birds. The lesions had a dark brown to black color. No lesions were found in oral cavity. Samples were taken for bacteriological, histopathological and hematological examinations.

The damaged areas of the nares and the beaks were cut, fixed in 10% formalin, decalcified by 2.5% nitric acid for 6 days and then embedded in paraffin and cut at 8 μ m. Serial sections were taken and stained with HandE, periodic acid shift and Gimsa. Epidermis, keratin layer and underlying connective tissue of the beaks were found to be severely affected by necrosis. Focal chondritis was another lesion but the cartilage and the bone in this part were intact. The clumps of leukocytes aggregated in the connective tissue were found in the vestibules of the nasal cavity (Fig. 2). No filamentous bacterium or hyphae of fungi were observed. A broad ring of densely-packed blue staining of the tissue debris containing bacteria was obvious in the beak epidermis (Fig. 3). The dermal layer was edematous and invaded by scant inflammatory cells. Large numbers of greatly dilated vessels were present in dermis (Fig. 3). In some cases in the deep layer of the dermis wherein trabecular bone is located, the erosion of the external surface of the bone was prominent (Fig. 4).

Swabs taken from lesions yielded mixed growth of hemolytic *Staphylococcus aureus*, *Staphylococcus intermedians*, *Staphylococcus latus* and a non-hemolytic *Streptococcus*. The feed materials cultured on Sabouraud dextrose agar yielded growth of *Aspergillus niger* and *Mocur spp.*

Discussion

There are several reports on beak lesions in chickens (1,2,3). Necrosis of the mandible in chicks, in cockerels (5), and in hens with around 10% mortality, probably mostly due to the beak necrosis and oral lesions in laying hens (4), have been described.

In an experimental study (2), a high incidence of beak lesions in broiler breeder males (74%) was observed but the incidence for females was much lower (6%). The development of oral and beak lesions was contributed to the direct or indirect injury of the epidermis followed by bacterial infection and tissue necrosis. It was discussed that food particles adhering to the beak may have predisposed the bird to the injury. Moisture beneath the nares, hemorrhages and scab formation may have helped feed adhering to the beak (2). In a recent study (6), oral lesions were induced in 100% of white leghorn laying hens fed on mash diet but very low incidence of lesions occurred when the crumble feed was used. Beak lesions or deformities, however, were rare. The most recent report has indicated the occurrence of the bilateral upper and lower beak lesions in 100% of males but not in females (3). Males were receiving the same feed as females but the feed bin and the feed pans were different (3).

In previous reports, bacteriological examinations of the beak lesions or surrounding area, have shown the growth of various bacteria such as *Pasteurella multocida*, *Staphylococcus aureus*, and *Streptococci* (2,3). In one study, the presence of a gram-positive keratinolytic bacterium in the electron microscopy sections of the beak tissue was reported (4). In our case report, swabs taken from lesions yielded mixed growth of hemolytic *Staphylococcus aureus*, *Staphylococcus intermedians*, *Staphylococcus latus* and a non-hemolytic *Streptococcus*. Mitevski (3) attempt failed to reproduce the beak lesions in 50-weeks-old roosters when the isolated bacteria from beaks and feed or mixtures of isolates or individual homogenate of beaks from affected animals were inoculated into the nostril



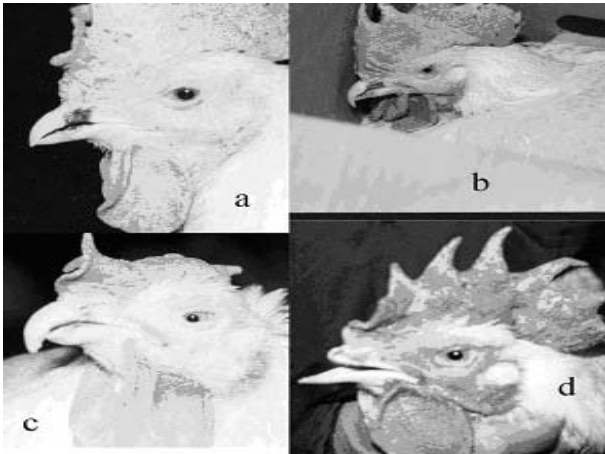


Figure 1. Beak lesions. (A) Necrosis of beneath nares, (B) Necrosis of upper and lower beak, (C) Lower beak detachment, (D) Upper beak breaking off.

of birds. The development of beak necrosis was attributed to the interaction among several factors such as bacteria, feed particle size, environment and sex (3). Mycotoxins have also been reported as the potential cause of oral lesions including the upper and lower beak in broilers (7).

In this report, beak lesions were found only in roosters without any oral lesion development. We postulated a diet low in protein and energy for roosters in the flock and an unsuitable roosters' feeders height provoked roosters to try eating from hens' troughs, covered with the wire grids, leading to the beak injuries. The fine mash diet and bacteria, possibly, prepared appropriate conditions leading to necrosis, conchitis and the beak deformation.

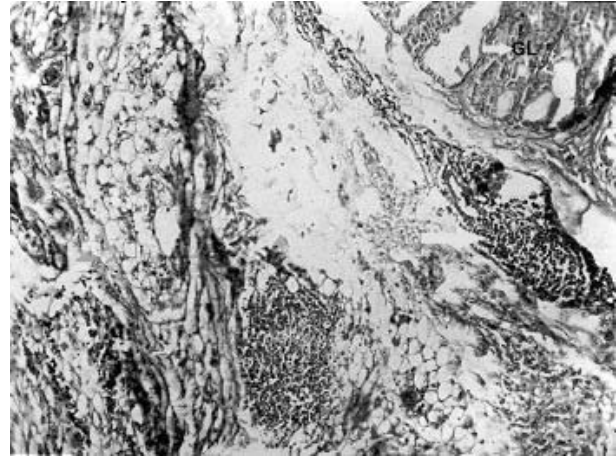


Figure 2. Vestibulitis in nasal cavity. The lamina propria of vestibule is plugged by accumulated leukocytes. Intact part of the gland (GL) is shown. (HandE x100).

Hematological profile differed from that of a previous report on food related oral lesions which in an experimental study found a mild anemia and a marked reduction in the numbers of heterophils, monocytes and eosinophils (8). In our observation, however, no anemia or decrease in the number of white blood cells was shown. The mild increase in the number of WBCs may be due to coanchitis. Higher PCV% in affected roosters could be caused by dehydration and emaciation.

The beak lesions observed in the flock reported here appeared to be a management-related problem. These findings have implications for poultry industry.




Figure 3. Severe lesions in epidermal layer (EP) showing advanced disintegration of this region. Bacterial colonies are embedded in tissue debris. The basal layer (DE) is virtually intact. (HandE x250).

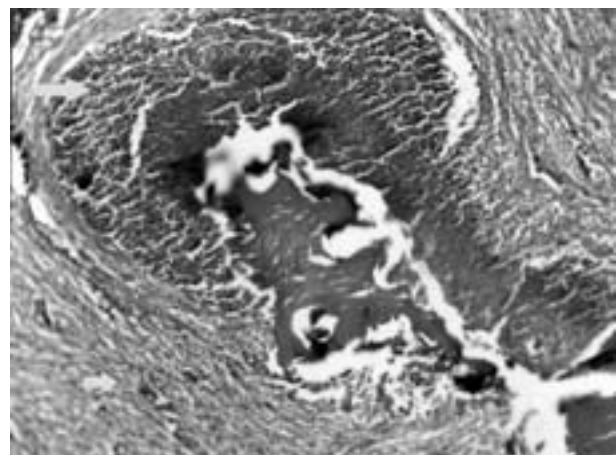


Figure 4. The spongy trabecular bone eroded by sheets of inflammatory cells. (HandE x400).



References

1. Barnes, H.J. (2003) Miscellaneous and sporadic bacterial infections. In *Diseases of Poultry*. Edited by YM Saif. 11th ed. Iowa State Press. Iowa, USA. pp.845-862.
2. Duff, S.R.I., Hocking, P.M., Randall, C.J. (1990) Beak and oral lesions in broiler breeding fowl. *Avian Pathol.* 19:451-466.
3. Mitevski, D. (2003) Beak necrosis in broiler breeder roosters. Presented in: the 14th Western Meeting of Poultry Clinicians and Pathologists, Lake Louise, Alberta. http://www.westvet.com/14th_wmpcp.htm.
4. Cheng, K.J., Gardiner, E.E., Costerton, J.W. (1976) Bacteria associated with beak necrosis in broiler breeder hens. *Vet. Rec.* 99:503-505.
5. Barr, M. (1965) Mandibular disease in stock cockerels. *Vet.Rec.* 77:667-679.
6. Daft, B., Read, D., Manzer, M., Bickford, A., Kinde, H. (2001) The influence of crumble and mash feed on oral lesions of white leghorn laying hens. *Avian Dis.* 45:349-354.
7. Ademoyero, A.A., Hamilton, P.B. (1991) Mouth lesions in broiler chickens caused by scirpenol mycotoxins. *Poult. Sci.* 70:2082-2089.
8. Gentle, M.J., Maxwell, M.H., Hunter, L.N., Seawright, E. (1989) Hematological changes associated with food related oral lesions in brown leghorn hens. *Avian Pathol.* 18:725-733.

