

Extracapsular Cataract Extraction (ECCE) in Dogs: Case Series

Short running title: Cataract Surgery in Dog

**Sina Yal Beiranvand¹, Shiva Amanollahi², Ehsan Lajmiri¹, Aliakbar Sabermoghadam³,
Hossein Kazemi Mehrjerdi^{1,*}**

¹ Department of Clinical Sciences, Faculty of Veterinary Medicine, Ferdowsi University of Mashhad, Mashhad, Iran

² Department of Clinical Sciences, School of Veterinary Medicine, Shiraz University, Shiraz, Iran

³ Khatam Eye Research Center and Hospital, Mashhad University of Medical Sciences (MUMS), Mashhad, Iran

Abstract

Background: Cataracts are one of the most common causes of blindness in dogs. Lens extraction can be a very successful technique for restoring vision. Postoperative consequences include uveitis, retinal detachments, corneal endothelial damage, capsular opacities, glaucoma, and hyphema. Various methods have been described for cataract surgery.

Objectives: Our center lacks a phacoemulsification instrument, so we used manual extracapsular cataract extraction (MECCE) in dogs with bilateral or unilateral cataracts to investigate this method's advantages and disadvantages.

Methods: A total of 27 MECCEs were done on 19 dogs. Before surgery, pupillary light reflex (PLR) and ultrasonography were performed, and the health of both eyes was evaluated with a microscope. Under general anesthesia, at first, a sizable corneal incision (about 180 degrees) was performed. Then the axial portion of the anterior lens capsule was excised for cataractous cortices and nucleus extraction.

Result: Eight Terrier-breeds and one Poodle-breed were represented with both eyes affected and the rest unilaterally affected. They included 9 male and 10 female dogs with an average age of

11.9 years (3 years to 16.2 years). The evaluation was done for 2 years. The restoration of functional vision was obtained in all eyes with unilateral or bilateral cataract extractions for almost two weeks postoperatively. No signs of endophthalmitis, glaucoma, *etc* were observed in any of the cases.

Conclusions: MECCE can be an excellent technique in cases where more facilities and phacoemulsification tools are unavailable.

Keywords: Cataract, Complication, Dog, Extracapsular extractions, Surgery

Introduction

In cataract disease, the lens comprises thin, transparent, highly organized protein fibers converted into white opacity. When the lens osmolality changes and is hydrated, it becomes opaque, prevents the passage of light, and eventually leads to blindness. But, diabetic cataracts, start with fluid accumulation and progress to blindness (Patil *et al.*, 2014). All breeds of small animals are mostly affected bilaterally. Cataracts are often classified into morphological,

etiological, and the degree of opacification (Gelatt and Wilkie, 2011). In the surgical context, a classification system that assesses the degree of cataract opacity or maturity is very useful, as this quantification of lens opacity correlates with clinical vision (Feng *et al.*, 2022). Cataract complications include lens-induced uveitis (LIU), posterior capsular opacification, increased intraocular pressure (Shokoohimand *et al.*, 2024), prolonged inflammation, retinal detachment, and persistent corneal edema. After lens removal, signs such as LIU, characterized by the slow or imperfect pupillary response to mydriatics, may progress; so, medical therapy is needed (Verloop and Read, 2023). Two common cataract surgical techniques are manual extracapsular cataract extraction (MECCE) and intra-ocular lens phacoemulsification (PHACO). In the MECCE surgical technique, the lens is extracted through a large corneal or limbal incision line. The PHACO technique removes lens material through a small incision with fragmentation, emulsification, and aspiration (Li *et al.*, 2022). The MECCE technique is a primitive procedure and the most common procedure that expert ophthalmologists perform when PHACO is unavailable. Also, due to the size and density of the cataractous lens and the thick capsule, MECCE is still recommended for canine cataracts (Davidson *et al.*, 1990; Beteg *et al.*, 2008).

This study investigated the functional vision and postoperative complications after 27 MECCEs in 19 dogs.

Material and methods

A retrospective study of 27 MECCEs was performed on 19 dogs with bilateral or unilateral cataracts. The sex, breed, age, and bilateral or unilateral MECCE of each animal were recorded in Table 1. Some of the dogs were sexually intact.

Table 1. Characteristics of cataract patients

Patient	Sex	Breed	Age (year)	Bilateral or unilateral Extracapsular cataract extraction
1	Female	Poodle	3.4	Bilateral
2	Female	Terrier	16.2	Bilateral
3	Female	Terrier	13.2	Unilateral
4	Female	Terrier	14	Bilateral

5	Female	Yorkshire Terrier	15	Unilateral
6	Female	Terrier	15.3	Bilateral
7	Male	Terrier	14.5	Bilateral
8	Male	Shih Tzu	16	Unilateral
9	Male	Terrier	13.5	Bilateral
10	Male	Chihuahua	10.3	Unilateral
11	Male	Terrier	9.1	Bilateral
12	Female	Terrier	15.5	Bilateral
13	Male	Terrier	3	Unilateral
14	Male	Yorkshire Terrier	12.5	Unilateral

15	Male	Cocker spaniel	15.2	Unilateral
16	Female	Maltese	14.8	Unilateral
17	Female	Poodle	11.3	Unilateral
18	Male	Poodle	8.5	Unilateral
19	Female	Poodle	5.2	Unilateral

Preoperative considerations

Preoperative, the systemic health, the pupillary light reflex (PLR), ultrasonography of the eyes with linear 7.5-15 MHz transducer (Esaote Mylab 30 gold CV, Via di Caciolle, Firenze, Italy) were assessed and observation of both eyes for ocular disease was performed under the microscope (Topcon, OMS-300, Japan). Medical treatments (24h before surgery) were topical prednisolone acetate 1% (one drop, q6h, Sina Darou, Tehran, Iran), topical ciprofloxacin 3% (one drop, q6h, Sina Darou, Tehran, Iran), systemic prednisolone (1 mg/kg⁻¹, q12h, Aburaihan pharmaceutical co, Tehran, Iran). Also, 90 min preoperatively, topical NSAID (Diclofenac

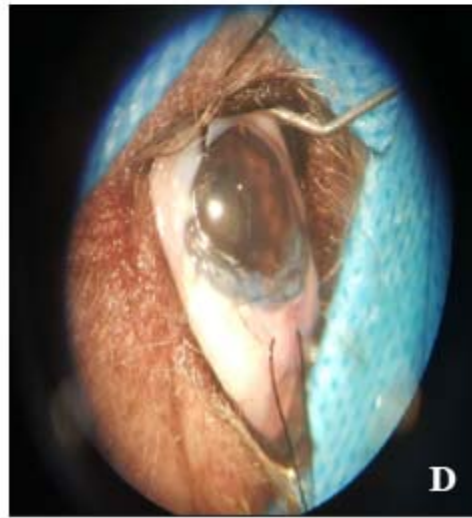
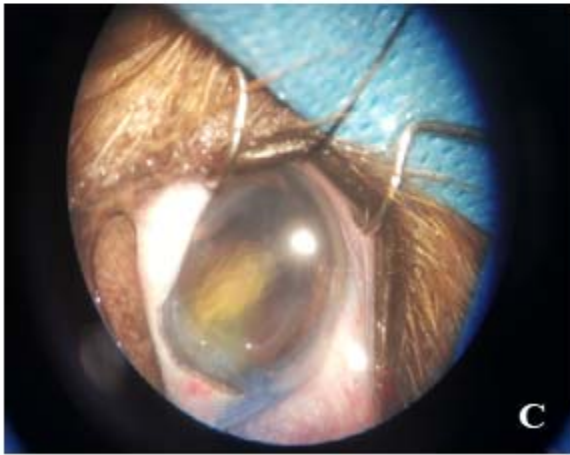
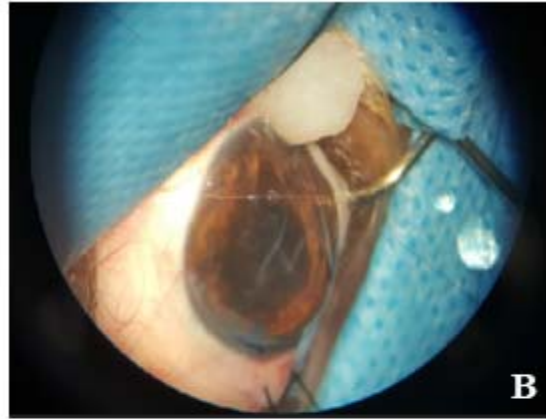
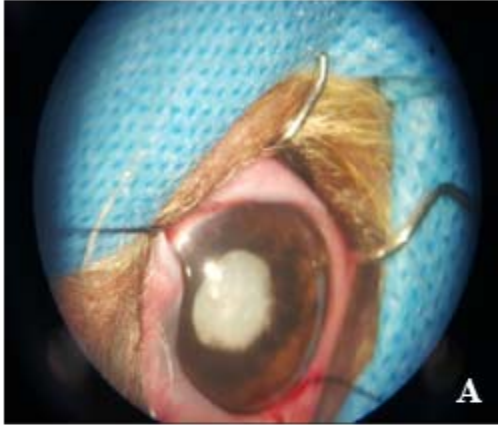
sodium 1%, one drop, q30 min, Sina Darou, Tehran, Iran) was used. Meloxicam 2% (0.2 mg/kg⁻¹, SC, Razak laboratories, Karaj, Iran) and cefazolin (22 mg/kg⁻¹, IV, q12, AFA Chemie Pharmaceutical Company, Tehran, Iran) injections were done before surgery and once 24 hours later. Topical tropicamide 1% (three drops, q6h, Sina Darou, Tehran, Iran) was administered 2 hours before surgery. Following premedication with Acepromazine (0.05 mg/kg⁻¹, IM, Neurotranq Alfasan, Holland), Propofol 1% (4 mg/kg⁻¹, IV, Braun Melsugen AG, Melsugen, Germany) as induction dose was injected and maintained with isoflurane gas (Aerrane, Guayama, Spanish) and 100% oxygen.

Surgical technique

The animals were placed in dorsal/lateral recumbency and around the eyes washed with a 5% povidone-iodine solution. Then the eyelids, corneal, and conjunctival surfaces were carefully flushed with lactated Ringer's solution (LRS). Their surfaces were cleansed with a 2% povidone-iodine solution. After the placement of the drape, the palpebral fissure was kept open with a lid speculum, and fixation of the eyeball and exposure was achieved using a silk 4-0 bridle suture. A peripheral (about 160-180°) corneal incision (from 9 O'clock to 3 O'clock on the superior cornea near the limbus) was performed to enter the anterior chamber (AC). First, a partial incision (90%

thickness) was made with the Beaver No. 6400 microsurgical blade. The AC was filled by air, and the anterior capsule was stained by trypan blue (Amp 1ml, Abzar Teb Pouya Co, Tehran, Iran) before the capsulorhexis to facilitate identification of the anterior lens capsule. After penetrating by a keratome, the incision was completed by a corneal scissor. The AC was kept during the capsulotomy procedure (can-opener technique) with viscoelastic material (Visicrom 2%, Croma Pharma GmbH, Austria).

The nucleus was expressed by simultaneous compression on the superior and inferior (6 and 12 o'clock) limbal area. Cataract cortices and lens material were aspirated by a Simcoe irrigation/aspiration cannula. The corneal incision was closed with a nonabsorbable suture (Nylon, 10-0, spatula needle, Kiyohara Industrial Park, Utsunomiya, Tochigi, Japan) in a continuous pattern (Shoelace). 90% of the thickness of the cornea was sutured to ensure the apposition of all layers of the cornea. Finally, the AC was reformed with LRS (Figure 1).



Un

Figure 1: Cataract surgery with MECCE method under the microscope. A) A view of the opacity white lens and corneal incision; B) Cataract lens extraction; C) Staining with Trypan blue; D) infusion of a viscoelastic solution and closing of corneal incision with Nylon, 10-0

Postoperative considerations

Topical ciprofloxacin 3% (one drop, q3h) and topical tropicamide 1% (three drops, q8h) were administered beginning the day of surgery for one week after surgery. Topical prednisolone acetate 1% (one drop, q3h) was administered for one month. Also, systemic ciprofloxacin (250 mg, 15 mg/kg⁻¹, PO, q12h, Tehran Darou Co, Iran) was administered for three days. The vision was evaluated by the dog's response to a menacing gesture and how it moved around. For the bilateral surgery group, each eye was assessed separately. By microscope and ophthalmoscopy, an ocular examination was performed on every operated eye for 1, 2, and 4 weeks, and every two months until two years post-surgery.

Results

In this report, the average age of the studied dogs was 11.9 years old. 10.53% of dogs were between 0–5 years old, 10.79% were between 5–10 years old, and 73.68% were between 10–15 years old. 52.63% of cases were female, and 47.36% were male. 57.90% of animals, unilaterally, and 42.10% of animals, bilaterally, suffered from cataracts. All animals were healthy and had no history of head trauma, ocular disease, *etc.* In ultrasonography, in all cases, the lens was abnormally echogenic and slightly thicker than usual, and the global size was within the normal limits in all cases (Figure 2). The pupillary light reflex was checked, which was positive in all dogs. In the follow-up, there were no signs of glaucoma (acute corneal edema and redness of the eyes in any case). In most cases, the patient had good vision during postoperative examinations. Only in one case, severe retinal atrophy was seen but the cause was unclear.

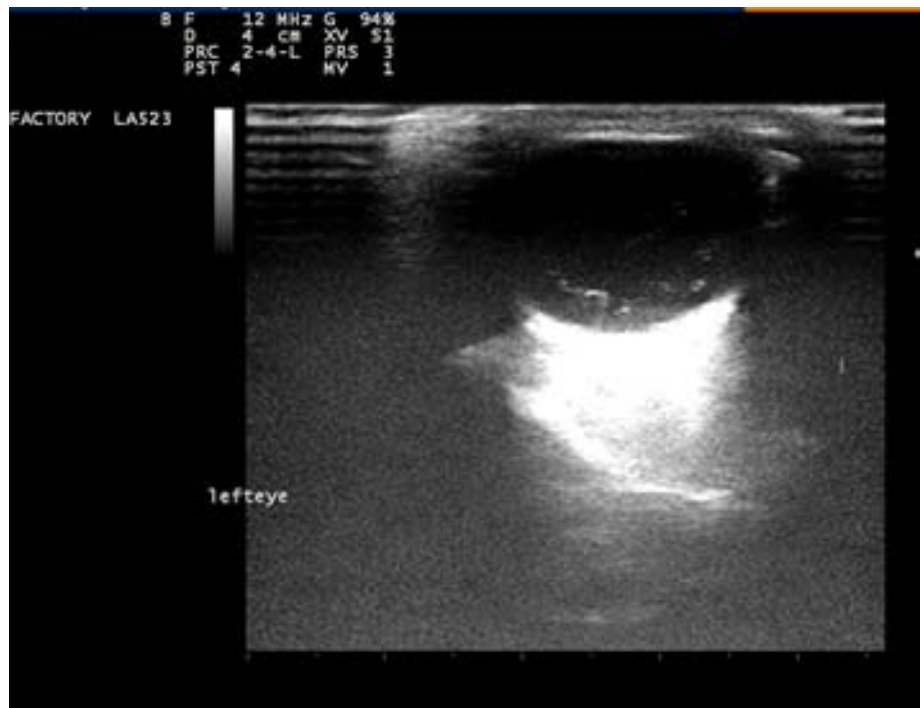


Figure 2: Ultrasonography of the mature cataract eye with linear transducer of 12 MHz.

Discussion

Cataract in dogs often develops as a result of the aging process and increases after 8 years old, but in young dogs at three years or less they may develop (Kibar *et al.*, 2014). Similar to our study, the average age of involvement in cataracts is reported to be over 8 years (Patil *et al.*,

2014; Chahory *et al.*, 2003; Guerra *et al.*, 2018). However, Heywood showed that the appearance and timing of cataracts in beagle dogs were up to 1 year of age. He stated that the early development of cataracts can depend on the breed of the animal (Heywood 1971). Also, Guerra *et al.* indicated that the most common breeds in the United Kingdom with cataracts are the Labrador Retriever and Jack Russell, which could be due to the incredible popularity of these two breeds in the UK (Guerra *et al.*, 2018); otherwise, similar to our study, cataracts can affect most dog breeds.

The symptoms of cataracts (uveitis, blindness) are often not recognized by dog owners, and they notice when the eye lenses have become white (Fischer *et al.*, 2018). At the stage of late maturity (mature cataract), vision is completely lost. Therefore, unlike humans, in dogs, cataracts are diagnosed at relatively late stages, resulting in hardening or liquefaction of the lens (Davidson *et al.*, 1990). In the ultrasonography, the abnormal echogenicity of the lens was confirmed. The thickness of the lens was higher than usual, and the global size was within the normal limits in all cases. In the clinical evaluation, the lens was opacified, also, surgery was needed. Cataract surgery is a selective treatment in animals to improve their quality of life. Therefore, the correct selection of the patient, especially in the early stages of the disease, is essential to maximize the successful surgical outcome (Fischer and Meyer-Lindenberg, 2014). In

the past years, the MECCE technique in dogs has been a standard and popular procedure for lens extraction. This method extracted the anterior lens capsule, lens cortex, and nuclear material (Patil *et al.*, 2014). Various studies have shown that surgery in the immature stages has a higher success rate than in the mature and hyper-mature stages. However, in the study of Leasure *et al.*, the comparison of tonometry results in different stages of cataract formation showed a significant difference only between the groups with immature and hyper-mature cataracts (Leasure *et al.*, 2001).

Today, the PHACO technique has been introduced as a standard method for cataract surgery due to smaller incisions and reduction of surgical time compared to the MECCE technique. The only disadvantage of this method is the high equipment and materials cost (Linebarger *et al.*, 1999). In the cataract cases of dogs, the size, the density of the cataractous lens, and the thickness of the capsule increased. So, the approach of MECCE as a primitive and economical method that does not need special equipment has been recommended (Patil *et al.*, 2014). In the preoperative assay, the pupillary light reflex was assessed, which was positive in all dogs; the absence reflex could be considered positive for retinal disease. Startup (1969) stated that pupillary response to light is an essential evaluation factor (Startup, 1969).

One of the reasons for the success of cataract surgery is the use of a suitable suture. Unlike some studies that used absorbable sutures (Vicryl, 7-0 to 9-0, simple interrupted or continuous pattern) (Biros *et al.*, 2000; Chahory *et al.*, 2003), in the present study, a corneal incision closed with 10-0 nylon suture contained a spatula needle with a continuous pattern (shoelace) that no need to remove the stitches. Only in one case, a loose suture was removed and then replaced. Patil *et al.* using the MECCE method after 3 months of follow-up, showed that the success percentage of this method was 75%. They used a 10-0 nonabsorbable monofilament suture, which is thinner than nylon 8-0, and no sutures were removed (Patil *et al.*, 2014). Also, in the study of Bonea, which used the MECCE method, the sclera, and the conjunctiva were sutured with 8-0 mono nylon in three separate stitches. However, in this study, after 30 days, posterior capsular opacification developed, and the dog had partial vision loss, but no other post-operative complication was observed (Bonea and Igna, 2022). In another study, the corneal incision was closed using simple sutures with 10-0 black nylon after successful PHACO surgery (Kang *et al.*, 2022). In other studies, the use of nonabsorbable threads such as silk 10-0 and prolene 8-0 in the MECCE method has also been reported (Patil *et al.*, 2014; Beteg *et al.*, 2008).

Cares and evaluations after each surgery show the degree of its success. In this study, the dogs became active and comfortable in the first days after the surgery. Most dogs had sufficient

vision to deal with obstacles at post-surgery examinations, which increased their self-confidence and ultimately helped improve their quality of life. Two weeks after surgery, clinical symptoms such as corneal opacity and posterior capsular fibrosis, which lead to definite corneal opacity, were not observed. If excessive handling and postoperative complications can be prevented, MECCE can be an alternative for owners who cannot afford lens costs and would like to resolve vision loss in their pets (Bonea and Igna, 2022).

Surgery is considered to have failed when dogs develop painful and blinding complications such as endophthalmitis, retinal detachment, or glaucoma (Bonea and Igna, 2022). Topical antibiotics, NSAIDs, and mydriatics reduce corneal edema, posterior capsular opacity, and anterior uveitis. In this study, preoperative administration of the topical NSAID and systemic NSAID were done. Chandler *et al.* recommended using COX-2 inhibitors to prevent posterior capsule opacification (Chandler *et al.*, 2007). Also, Yi *et al.* recommended a single intravenous dose injection of Flunixin Meglumine at the time of induction of anesthesia is advantageous in preventing fibrin formation (Yi *et al.*, 2006). Among the symptoms of glaucoma are acute corneal edema and redness of the eyes (Moumneh *et al.*, 2020). In the follow-up, there were no signs of glaucoma (acute corneal edema and redness of the eyes in any case).

Despite advanced techniques, PHACO cataract surgery is not yet available in some centers, and due to the capsular thickness, hardness, and larger cataract lens, as well as canine lenses not being available or affordable, the MECCE procedure can be a valid technique in cataract surgery in dogs. Although the number of animals studied is minimal, reporting successes of the MECCE method can greatly contribute to canine cataract treatment.

Acknowledgments

The authors thank the staff of the Faculty of Veterinary Medicine Teaching Hospital of Ferdowsi University of Mashhad for their cooperation.

Funding

This research did not receive any grant from funding agencies in the public, commercial, or non-profit sectors.

Conflict of interest

The authors declare no conflict of interest.

Consent to participate

In this study, we gave enough information to the animal owners about the type of operation, and consent was obtained from them.

References:

- Beteg F, Muste A, MATEȘ N, OANĂ L. (2008). Cataracts Surgery in Dog by Extracapsular Extraction, Mini-Nuc Method. *Lucrărilor științifice Medicină Veterinară*, 41,519-25. https://www.usab-tm.ro/vol8MV/79_vol8.pdf
- Biros DJ, Gelatt KN, Brooks DE, Kubilis PS, Andrew SE, Strubbe DT, et al. (2000). Development of Glaucoma after Cataract Surgery in Dogs: 220 Cases (1987–1998). *Journal of the American Veterinary Medical Association*. 216(11):1780-6. <https://doi.org/10.2460/javma.2000.216.1780>
- Bonea E, Igna C. (2022). Efficiency and Therapeutic Conduct of Surgical Procedures for Mature Cataracts in a Dog, Case Report. *Scientific Works. Series C, Veterinary Medicine*. 68(1). https://veterinarymedicinejournal.usamv.ro/pdf/2022/issue_1/Art8.pdf
- Chahory S, Clerc B, Guez J, Sanaa M. (2003). Intraocular Pressure Development after Cataract Surgery: A Prospective Study in 50 Dogs (1998–2000). *Veterinary Ophthalmology*. 6(2):105-12. <https://doi.org/10.1046/j.1463-5224.2003.00263.x>
- Chandler HL, Barden CA, Lu P, Kusewitt DF, Colitz CM. (2007). Prevention of Posterior Capsular Opacification through Cyclooxygenase-2 Inhibition. *Molecular Vision*. 13:677. <https://pubmed.ncbi.nlm.nih.gov/17563718>
- Davidson MG, Nasisse MP, Rusnak M, Corbett WT, English RV. (1990). Success Rates of Unilateral vs. Bilateral Cataract Extraction in Dogs. *Veterinary Surgery*. 19(3):232-6. <https://doi.org/10.1111/j.1532-950x.1990.tb01176.x>

Feng L, Zhao F, Ke X, Zhao J, Shi M. (2022). Correlation Between Degree of Lens Opacity and the Phacoemulsification Energy Parameters Using Different Imaging Methods in Age-Related Cataract. *Translational Vision Science & Technology*. 11(3):24-. <https://doi.org/10.1167%2Ftvst.11.3.24>

Fischer MC, Meyer-Lindenberg A. (2014). Cataracts in Dogs--Overview and Guideline for Decision Making in Treatment. *Tierärztliche Praxis. Ausgabe K, Kleintiere/Heimtiere*. 42(6):411-23. <https://doi.org/10.15654/tpk-140877>

Fischer MC, Meyer-Lindenberg A. (2018). Progression and Complications of Canine Cataracts for Different Stages of Development and Aetiologies. *Journal of Small Animal Practice*. 59(10):616-24. <https://doi.org/10.1111/jsap.12910>

Gelatt KN, Wilkie DA. (2011). Surgical Procedures of the Lens and Cataract. *Veterinary Ophthalmic Surgery*. 305-55.

Guerra R, Cabeças R, Diaz J, Knott T, Freitas I, Vilhena H, et al. (2018). Cataracts in Labrador Retriever and Jack Russell Terrier from the United Kingdom: A Two-Year Retrospective Study. *Topics in Companion Animal Medicine*. 33(4):109-13. <https://doi.org/10.1053/j.tcam.2018.09.001>

Heywood R. (1971). Juvenile Cataracts in the Beagle Dog. *Journal of Small Animal Practice*. 12(3):171-7. <https://doi.org/10.1111/j.1748-5827.1971.tb06215.x>

Kang MG, Han DH, Han SM, Jung EG, Kim GM, Cho JH, et al. (2022). A Case of Cataract Surgery Using Phacoemulsification in a 12-Year-Old Poodle. *Korean Journal of Veterinary Service*. <https://doi.org/10.7853/kjvs.2022.45.3.221>

Kibar M, Evreklioglu C, Dogan Z. (2014). Treatment of Ophidism-Induced Bilateral Canine Cataract by Extracapsular Lens Extraction and Intraocular Lens Implantation. *Iranian Journal of Veterinary Research*. 15(4):416. <http://www.ncbi.nlm.nih.gov/pmc/articles/pmc4789225/>

Leasure J, Gelatt KN, MacKay EO. (2001). The Relationship of Cataract Maturity to Intraocular Pressure in Dogs. *Veterinary Ophthalmology*. 4(4):273-6. <https://doi.org/10.1046/j.1463-5216.2001.00199.x>

Li A, He Q, Wei L, Chen Y, He S, Zhang Q, et al. (2022). Comparison of Visual Acuity between Phacoemulsification and Extracapsular Cataract Extraction: A Systematic Review and Meta-Analysis. *Annals of Palliative Medicine*. 11(2):55159-559. <https://apm.amegroups.org/article/view/89411/html>

Linebarger EJ, Hardten DR, Shah GK, Lindstrom RL. (1999). Phacoemulsification and Modern Cataract Surgery. *Survey of Ophthalmology*. 44(2):123-47. [https://doi.org/10.1016/s0039-6257\(99\)00085-5](https://doi.org/10.1016/s0039-6257(99)00085-5).

Moumneh K, Sheybani A, Fellman RL, Godfrey DG, Grover DS. (2020). Reticular Corneal Edema or Corneal Honeycombing in Eyes Treated with Netarsudil: A Case Series. *Journal of Glaucoma*. 29(7):607-10. <https://doi.org/10.1097/ijg.0000000000001516>.

Patil VN, Patil PB, Parikh PV, Talekar SH, Patil DB, Kelawala NH, et al. (2014). Cataract and ECCE—An Evaluation on 60 Canine Cases Registered at Anand, Gujarat (India) Region. *European Journal of Biomedical and Pharmaceutical Sciences* 3:326-9.

https://www.researchgate.net/publication/269094551_Cataract_and_ECCE_-_An_evaluation_on_60_canine_cases_registered_at_Anand_Gujarat_India_region

Patil VN, Patil PB, Parikh PV, Talekar SH, Patil DB, Kelawala NH, et al. (2014). Extra Capsular Cataract Surgery in Canine—a Pictorial View. *International Journal of Veterinary Science & Research*. 1(1):1-6. https://www.researchgate.net/publication/267034293_EXTRA_CAPSULAR_CATARACT_SURGERY_IN_CANINE_-_A_PICTORIAL_VIEW

Shokoohimand A, Arfaee F, Asghari A, Khaksar E. Short-term vs. Long-term Effects of Topical administration of latanoprost on Schirmer Tear Test, Intraocular Pressure, and Pupil Size in Clinically Normal Dogs. *Iranian Journal of Veterinary Medicine*. 2024 Oct 6.

Startup FG. (1969). Cataract Surgery in the Dog. *Journal of Small Animal Practice*. 10(8):457-60. <https://doi.org/10.1111/j.1748-5827.1967.tb04513.x>.

Verloop AB, Read RA, Anastassiadis Z. (2023). Posterior Lens Capsule Rupture in Non-diabetic Canine Cataracts: Pre-operative, Intra-operative, and Post-operative Findings. *Veterinary Ophthalmology*. 26(1):12-8. <https://doi.org/10.1111/vop.13050>

Yi NY, Park SA, Jeong MB, Kim WT, Kim SE, Chae JM, et al. (2006). Phacoemulsification and Acryl Foldable Intraocular Lens Implantation in Dogs: 32 Cases. *Journal of Veterinary Science*. 7(3):281-5. <https://doi.org/10.4142%2Fjvs.2006.7.3.281>.

Uncorrected Proof

استخراج آب مروارید به روش خارج کپسولی در سگ: گزارش موارد

سینا یل بیرانوند¹، شیوا امان‌الهی²، احسان لجمیری¹، علی‌اکبر صابرمقدم³، حسین کاظمی‌مهرجردی^{1*}

¹ گروه علوم درمانگاهی، دانشکده دامپزشکی، دانشگاه فردوسی مشهد، مشهد، ایران

² گروه علوم درمانگاهی، دانشکده دامپزشکی، دانشگاه شیراز، شیراز، ایران

³ مرکز تحقیقات چشم و بیمارستان خاتم، دانشگاه علوم پزشکی مشهد، مشهد، ایران

چکیده

زمینه مطالعه: یکی از شایع‌ترین دلایل نابینایی در سگ‌ها آب مروارید است. خروج لنز می‌تواند یک تکنیک بسیار موفق برای بازگرداندن بینایی بیمار باشد. پیامدهای بعد از عمل شامل التهاب داخل چشم، جداشدگی شبکیه، آسیب اندوتلیال قرنیه، کدورت کپسولی، افزایش فشار چشم و خونریزی داخل اتاق قدامی چشم است. روش‌های مختلفی برای جراحی آب مروارید شرح داده شده است.

هدف: با توجه به عدم وجود ابزار فیکوامولسیفیکاسیون در مرکز ما، از روش خروج دستی آب مروارید به روش خارج کپسولی (MECCE) در سگ‌های مبتلا به آب مروارید دو طرفه یا یک طرفه برای بررسی مزایا و معایب این روش استفاده شد.

روش کار: در مجموع 27 جراحی به روش MECCE بر روی 19 سگ انجام شد. قبل از جراحی، رفلکس نور مردمک (PLR) و سونوگرافی انجام و سلامت هر دو چشم با میکروسکوپ بررسی شد. تحت بیهوشی عمومی، ابتدا برش قابل توجهی (حدود 180 درجه) بر روی قرنیه زده شد. سپس قسمت محوری کپسول عدسی قدامی برای خروج قشر آب مروارید و هسته برداشته شد.

نتایج: هشت نژاد تریر و یک نژاد پودل با هر دو چشم مبتلا و بقیه به‌طور یک طرفه مبتلا بودند. آن‌ها شامل 9 سگ نر و 10 سگ ماده با میانگین سنی 11.9 سال (3 سال تا 16.2 سال) بودند. ارزیابی به مدت 2 سال انجام شد. عملکرد بینایی در همه چشم‌ها با خروج یک طرفه یا دو طرفه کاتاراکت، تقریباً طی دو هفته بعد از عمل بازگشت. در هیچ یک از موارد علائم التهاب پوشش‌های داخلی چشم، افزایش فشار چشم و غیره مشاهده نشد.

نتیجه گیری نهایی: MECCE می‌تواند یک تکنیک عالی در مواردی باشد که امکانات بیشتر و ابزارهای فیکوامولسیفیکاسیون در دسترس نباشد.

کلمات کلیدی: آب مروارید، عارضه، سگ، استخراج خارج کپسولی، جراحی

Uncorrected Proof